

Lehigh Valley Health Network
LVHN Scholarly Works

Department of Surgery

Appendiceal Mucocele Intussusception

Christine W. Du MD

Lehigh Valley Health Network, Christine_W.Du@lvhn.org

Rovinder S. Sandhu MD

Lehigh Valley Health Network, Rovinder_S.Sandhu@lvhn.org

Follow this and additional works at: <https://scholarlyworks.lvhn.org/surgery>



Part of the [Other Medical Specialties Commons](#), and the [Surgery Commons](#)

Let us know how access to this document benefits you

Published In/Presented At

Du, C. W., & Sandhu, R. S. (2011). Appendiceal Mucocele Intussusception. *LVHN Scholarly Works*.

Retrieved from <https://scholarlyworks.lvhn.org/surgery/2>

This Poster is brought to you for free and open access by LVHN Scholarly Works. It has been accepted for inclusion in LVHN Scholarly Works by an authorized administrator. For more information, please contact LibraryServices@lvhn.org.

Appendiceal Mucocele Intussusception

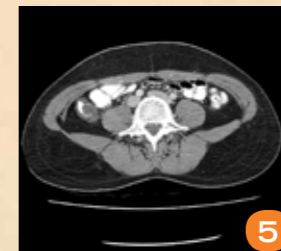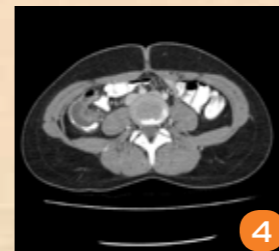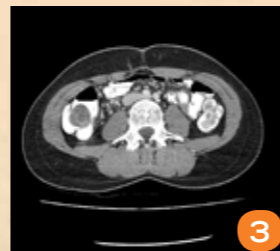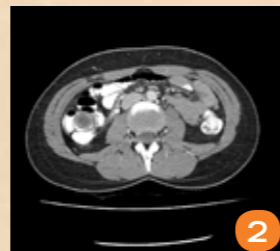
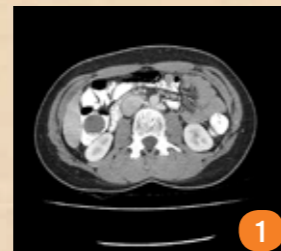Christine Du, MD and Rovinder Sandhu, MD, Lehigh Valley Health Network, Allentown, Pennsylvania

Introduction

Appendiceal mucocele is a rare disease. It can present with numerous clinical symptoms, such as right lower quadrant abdominal pain, palpable mass and gastrointestinal bleeding. It can also be found incidentally in surgical specimens. The incidence has been reported as 0.2-0.4% of all appendiceal specimens. It is histologically divided into four subtypes: mucinous hyperplasia, mucinous cystadenocarcinomas, mucosal hyperplasia, and retention cyst.

Patients with benign mucocele have a 5-year survival rate of 100% and those with a malignant mucocele have a 5-year survival rate of 45%. Ruptured mucoceles that cause peritoneal contamination regardless whether they are benign or malignant have much poorer outcomes.

Unlike the pediatric population where intussusception without peritonitis treatment can be attempted with reduction, with adult intussusception, there should be no attempt in reduction, only surgical resection

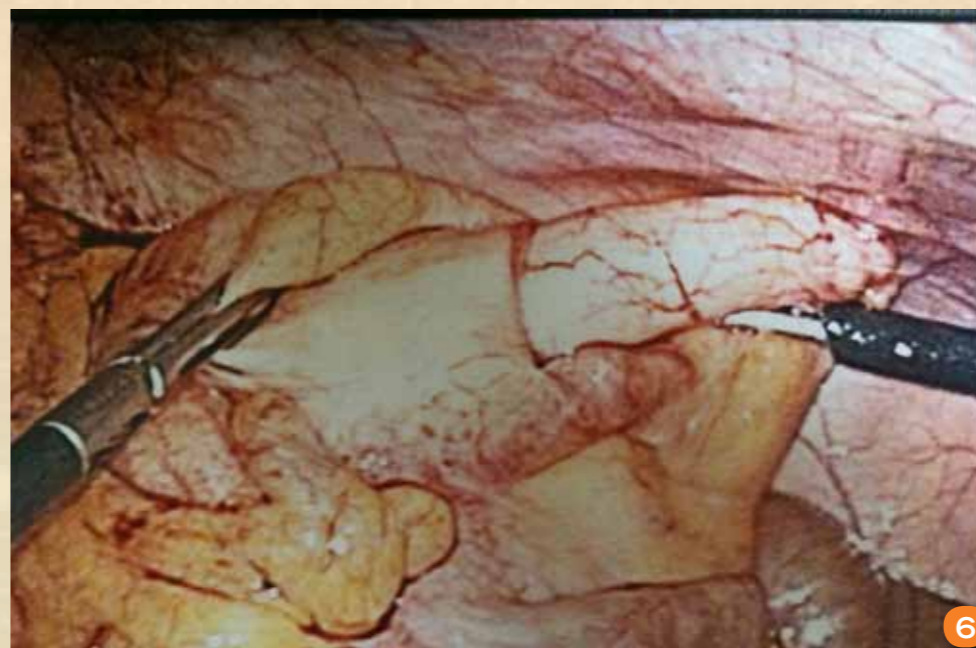


Case Report

23 year old female has a three week history of right-sided abdominal pain presenting to the Emergency Department. She has no significant past medical or surgical history. On presentation, she was hemodynamically stable. Her abdominal exam was soft, but had moderate right lower quadrant tenderness to palpation with no rebound or guarding. CBC, BMP and U/A were all within normal limits. CAT scan of the abdomen and pelvis was obtained and demonstrated an ileocolic intussusception with questionable mucocele within the cecum. (Fig. 1-5)

Intraoperative finding was an ileocolic intussusception with the appendix as the lead point. (Fig. 6) The intussusception was not reduced. She underwent a laparoscopic-assisted right hemicolectomy. Her postoperative course was uncomplicated and was discharged on postoperative day 3. Final pathology revealed a 4cm low-grade appendiceal mucinous neoplasm with associated intussusception into the cecum. The proximal ileal and distal colonic margins were negative for tumor.

Fig. 1-5 : CAT scan of the abdomen and pelvis demonstrating an ileocolic intussusception.
Fig. 6: Intraoperative finding of an appendiceal mucocele intussusception.



Discussion

An appendiceal mucocele presenting as an intussusception is uncommon. Literature review found no consensus in the long-term follow-up. Appendiceal mucocele is related to tumors and about 11-20% of patients have colonic adenocarcinoma. Follow-up is required because recurrences can occur as well as colonic and/or ovarian neoplasms. This includes repeat imaging, colonoscopy as well as gynecologic pelvic exams.

References

- Greenfield's Surgery: Scientific Principles and Practice. 2010.
- Karakaya, K et al. Appendiceal mucocele: Case reports and review of current literature. World Journal of Gastroenterology. Apr 2008; 14(14):2280-2283.
- Palanivelu, C et al. Laparoscopic Right Hemicolectomy for Mucocele Due to a Low-Grade Appendiceal Mucinous Neoplasm. Journal of the Society of Laparoscopic Surgeons. 2008; 12:194-197.
- Zagrodnik, D et al. Mucinous Cystadenoma of the Appendix: Diagnosis, Surgical Management and Follow-Up. Current Surgery. 2003 (60)3: 341-343.