

Atypical Lymphocytic Lobular Panniculitis: A Distinct eEntity in the Spectrum of Cutaneous Lymphoid Dyscrasia

Lusia S. Yi DO, MS

Philadelphia College of Osteopathic Department of Medicine, Lehigh Valley Health Network,
Lusia_S.Yi@lvhn.org

Nicole Bright DO

Philadelphia College of Osteopathic Department of Medicine

Stephen Purcell DO

Philadelphia College of Osteopathic Department of Medicine, Lehigh Valley Health Network,
Stephen.Purcell@lvhn.org

Follow this and additional works at: <https://scholarlyworks.lvhn.org/medicine>



Part of the [Dermatology Commons](#), and the [Medical Sciences Commons](#)

Let us know how access to this document benefits you

Published In/Presented At

Yi, L., Bright, N., & Purcell, S. (2011). *Atypical lymphocytic lobular panniculitis: A distinct entity in the spectrum of cutaneous lymphoid dyscrasia*. Poster presentation.

This Poster is brought to you for free and open access by LVHN Scholarly Works. It has been accepted for inclusion in LVHN Scholarly Works by an authorized administrator. For more information, please contact LibraryServices@lvhn.org.

Atypical Lymphocytic Lobular Panniculitis: a distinct entity in the spectrum of cutaneous lymphoid dyscrasia

^{1,2}Lusia Yi, DO, MS, ²Nicole Bright, DO, ^{1,2}Stephen Purcell DO

¹Lehigh Valley Health Network, Allentown, Pennsylvania; ²Philadelphia College of Osteopathic Medicine, Philadelphia, PA

Abstract:

We report a case of atypical lymphocytic lobular panniculitis (ALLP) characterized by recurrent subcutaneous nodules with similar molecular and phenotypic profile of cutaneous T-cell lymphoma. A twenty-one year old female presented with a six-year history of recurrent erythema nodosum on the lower extremities. The histopathology revealed a lobular panniculitis composed of histiocytes and slightly atypical, predominately CD3 positive lymphocytes consistent with the diagnosis of ALLP. ALLP represents a spectrum of cutaneous lymphoid dyscrasia characterized by recalcitrant and insidious clinical course and atypical lymphocytic infiltration that do not fulfill the diagnostic criteria of lymphoma. Due to its possible association with subcutaneous panniculitis-like T-cell lymphoma and potential for malignant transformation, recognizing ALLP as a distinct entity is important in understanding the clinical and management spectrum of lymphocytic lobular panniculitis.

Case Presentation:

HPI: -one year old female with a six-year history of recurrent “erythema nodosum”. Reports painful and pruritic lesions on the lower extremities that usually resolve spontaneously within one month and recurs about one to two episodes per year. No prodromal symptoms.

ROS: Mild intermittent shortness of breath and joint pain

PMHx/Family Hx: Non-contributory

PE: Afebrile, alert female without acute distress. Multiple indurated, erythematous, subcutaneous, tender nodules and plaques located on the forearms and lower extremities. No lower extremity edema.

Laboratory Evaluation: Mildly elevated erythrocyte sedimentation rate of 33 (0-20mm/hr). Complete blood count, rheumatoid factor, antinuclear antibody, and streptolysin O antibody were all negative and within normal limits.

Skin biopsy of nodule on the right medial calf:

Histopathology- mild spongiosis and focal haphazard migration of lymphocytes into the epidermis, patchy mild perivascular and periappendageal lymphocytic infiltrate with rare eosinophils extending into the deep dermis, mildly increased dermal mucin seen by Alcian Blue stain, and a subcutaneous lobular inflammatory infiltrate composed of histiocytes and small to intermediate size, mildly atypical lymphocytes (figure 1). No erythrocyte phagocytosis.

Phenotypic studies of inflammatory infiltrate using immunohistochemical stains- co-expression of predominantly CD3 and CD2 positive T cells. CD5 and CD7 cells expressed without prominent loss of antigenicity. No prominent CD30 positive or CD56 positive cells. CD68 positive cells consistent with histiocytes were seen.

PCR-T cell receptor gamma chain gene - rearrangement of inflammatory infiltrate-polyclonal.

Diagnosis: Atypical lymphocytic lobular panniculitis

Treatment: Systemic corticosteroids, indomethacin, and naproxen for pain control. However, the lesions recurred and most recent episode involved buttocks and abdomen (figure 2).

DIFFERENTIAL DIAGNOSIS

- Subcutaneous panniculitis-like T cell lymphoma (STCL)
- Lupus erythematosus panniculitis (LEP)

Table 1. Comparison of clinical features of ALLP, STCL, and LEP

	ALLP	STCL	LEP
Clinical Presentation	M=F Young adults	M=F Young adults	F>M Middle aged adults
Lesions	Chronic recurrent subcutaneous nodules Extremities	Progressive subcutaneous nodules with ulceration Extremities	Chronic recurrent subcutaneous nodules Face with other +/- LE lesions
Extracutaneous Manifestation	Rare	Common Fever, malaise, fatigue, weight loss Hemophagocytic syndrome	Less common Serologic abnormalities End organ dysfunction

M = male, F = female, LE = lupus erythematosus

Table 2. Comparison of histopathologic features of ALLP, STCL, and LEP

	ALLP	STCL	LEP
Histopathologic	Moderate infiltrate Mild atypia No fat necrosis Rare mixed cells	Dense infiltrate Severe atypia Apoptosis, angioinvasion, fat necrosis Rare mixed cells	Mild-mod infiltrate No atypia Septal fibrosis and prominent mucin B-cell follicles, plasma cells
Immunophenotypic	↓ CD5, CD7 cells	↓ ↓ CD5, CD7 cells Predominant cytotoxic CD8 cells	T & B-cells DIF: IgG and C3 deposition at BMZ
Molecular	Monoclonal	Monoclonal/Polyclonal	Polyclonal

DIF - Direct immunofluorescence, BMZ: Basement membrane zone

TREATMENT

- Goal of treatment is to halt the progression to lymphoma
- Corticosteroids and nonsteroidal anti-inflammatories for pain
- Oral retinoid therapy for persistent lesions
- Case series by Magro et al. reported treatments with dapson, hydroxychloroquine, interferon, and anti-CD52 monoclonal antibody alemtuzumab, which is currently approved for the treatment of chronic lymphocytic leukemia

PROGNOSIS

- Exact prognosis remains unknown
- Reported cases of ALLP follow an indolent course and no reported cases of ALLP progressing to STCL
- However, few cases of STCL where history of waxing and waning patterns have been observed
- Persistent identical T-cell clone at different biopsy sites over time has been demonstrated in ALLP
- Therefore, ALLP may represent a preneoplastic phase of STCL and close monitoring and follow up is warranted
- Recommend repeat biopsy and laboratory studies with changes in clinical symptoms, lesion morphology, distribution, progression, and therapy responsiveness

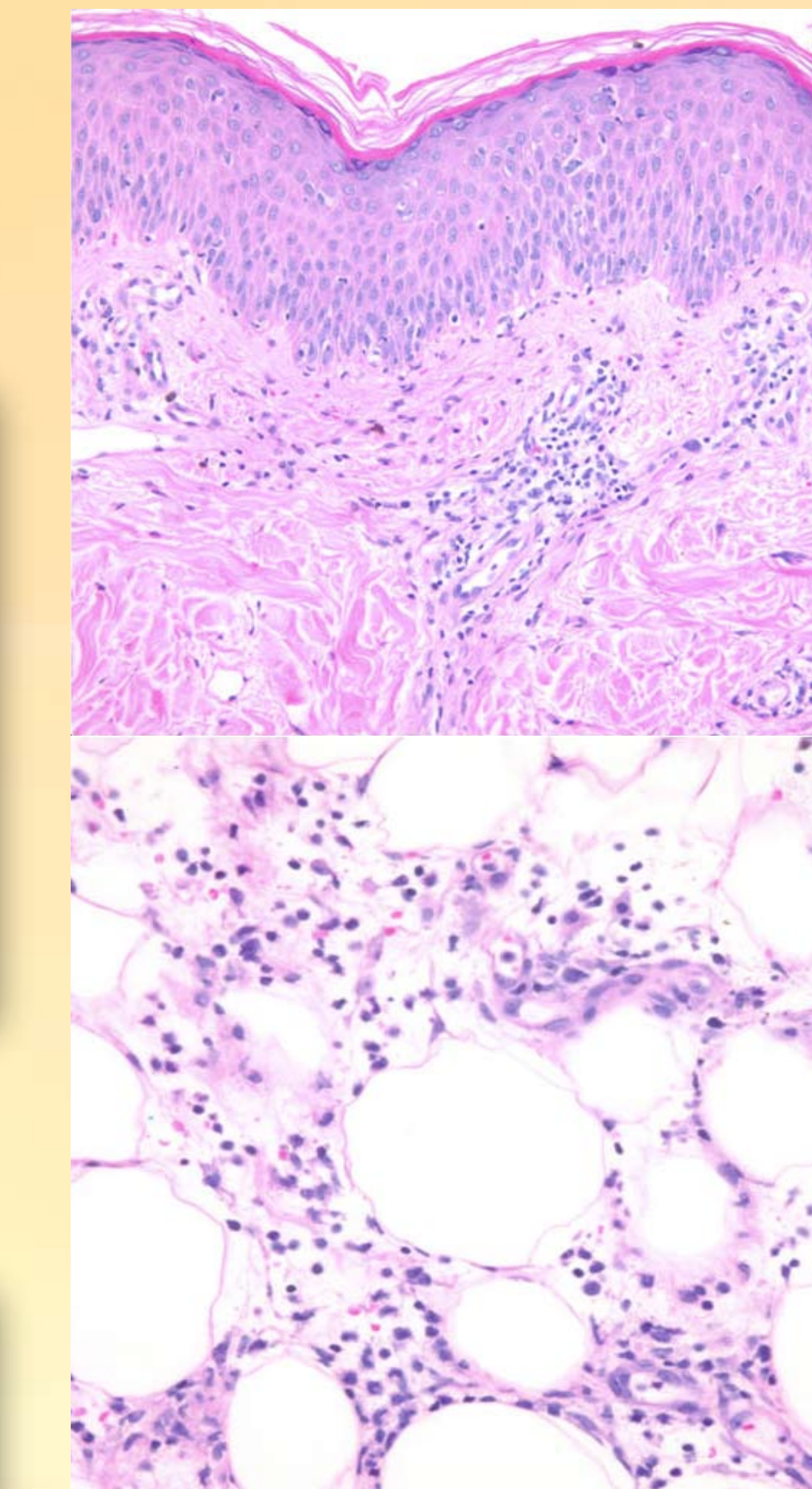


Figure 1. (A) 20X magnification- Epidermal and dermal involvement are minimal in ALLP. Epidermis may show subtle lymphocytic exocytosis. (B) 40X magnification- Lymphoid infiltrate of small to medium sized cells within the subcutaneous tissue in lobular pattern.

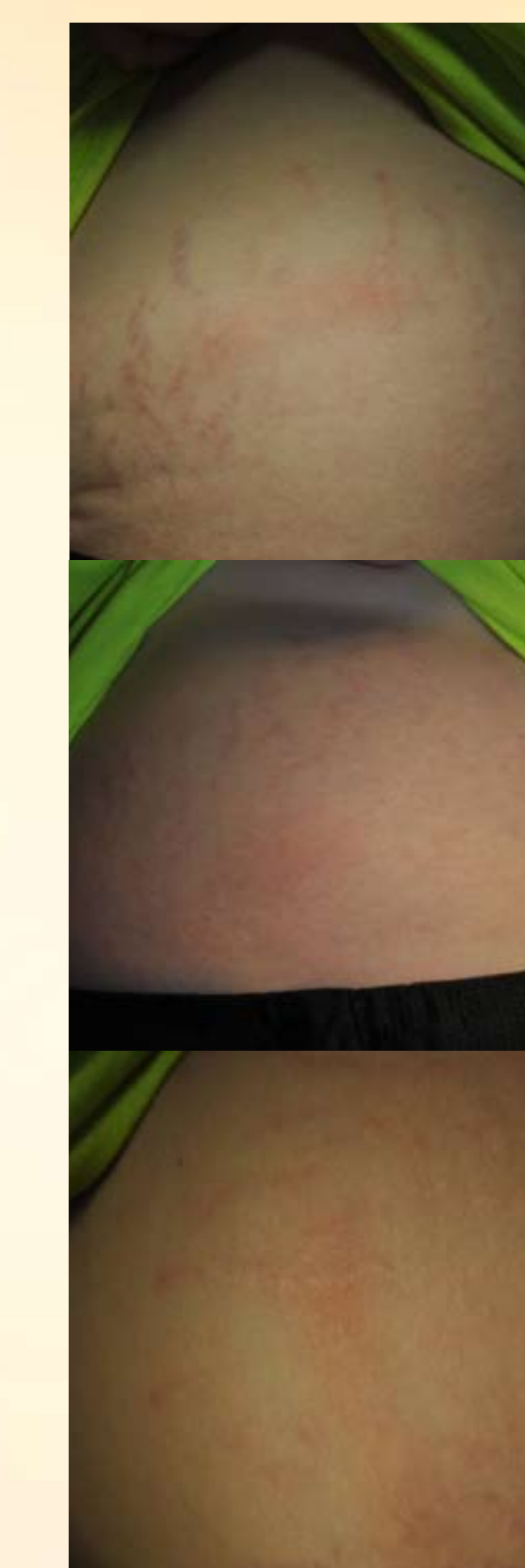

Figure 2. Indurated, erythematous, subcutaneous, tender nodules on the abdomen.

Discussion:

ALLP as described by Magro et al. represents a spectrum of disorders with recalcitrant and insidious clinical course and atypical lymphocytic infiltration. Other disorders in this spectrum include alopecia mucinosa, pityriasis lichenoides chronica, large plaque parapsoriasis, idiopathic follicular erythroderma, mucinosis, pigmented purpuric dermatoses, and atypical hypopigmented interface variant dermatoses.

Some authors suggest that ALLP is a concomitant presentation or overlap of STCL and LEP. Willemze et al. reported that 19% of STCL patients had an associated autoimmune disorder with lupus erythematosus (LE) being the most common. There are reported cases where diagnosis of earlier LEP has been changed to STCL. Pincus et al observed one STCL patient with a positive DIF test without histopathologic feature of LE. Monoclonal pattern has been demonstrated in 70 to 75% of ALLP patients. Therefore, the use of TCR gene rearrangement study in distinguishing the ALLP from malignant process should be made with caution. Initial screening should include rheumatologic work up including complete blood count, rheumatoid factor, antinuclear antibody, and erythrocyte sedimentation. Similarly, LEP patients should also be followed closely due to its close association with STCL. Perhaps ALLP may represent a continuum of inflammatory disarray from chronic antigenic stimulation. This stimulation then can prime the initial benign process to possible clonal selection and proliferation leading to malignant transformation (figure 3).

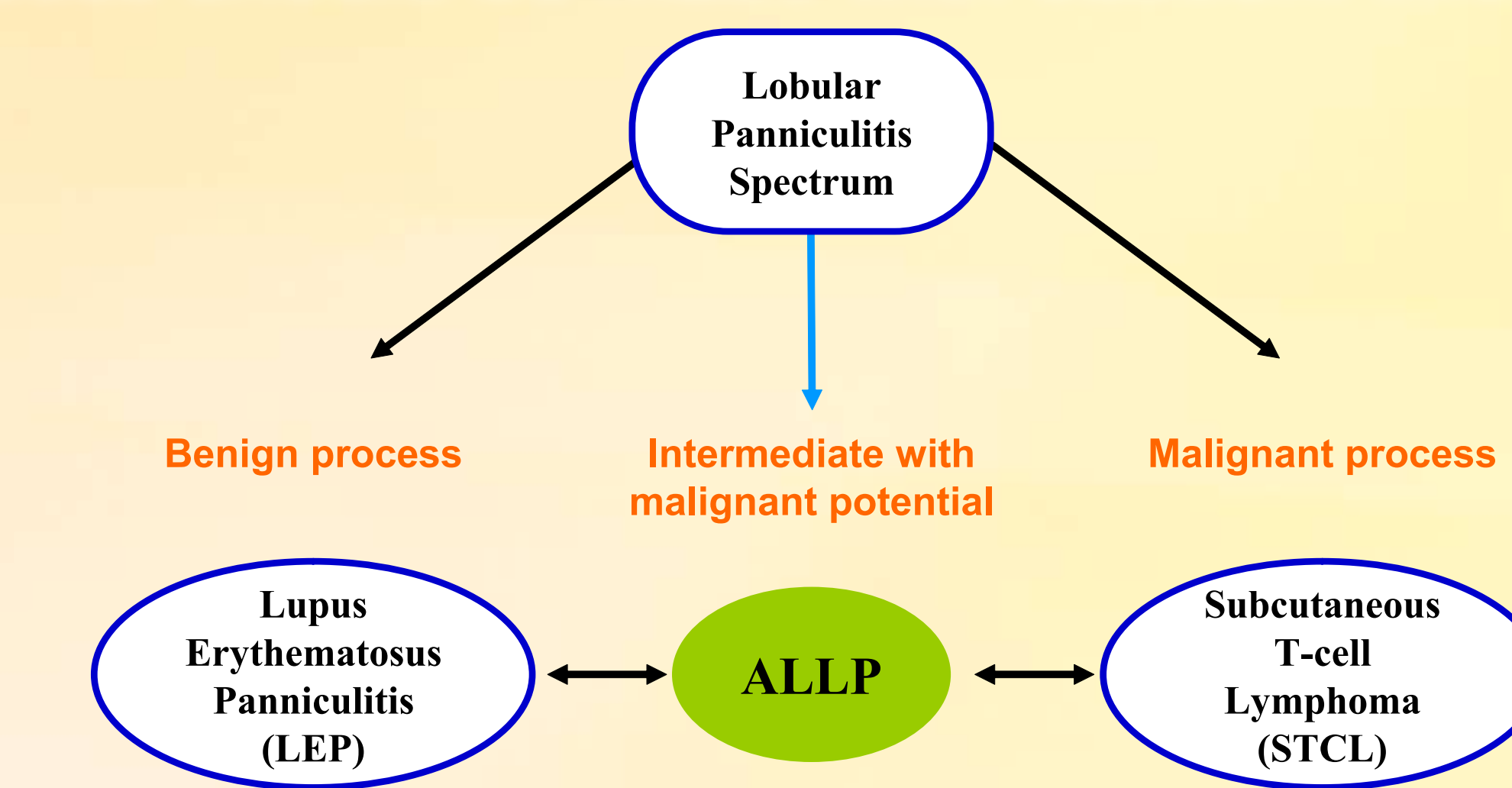


Figure 3. Proposed schematic representation of lymphocytic lobular panniculitis as a spectrum of inflammatory disarray from chronic antigenic stimulation.

References:

- 1 Aguilera P, Mascaro JM, Martinez A, Esteve J, Puig S, Campo E, Estrach T. Cutaneous gamma/delta T-cell lymphoma: A histopathologic mimicker of lupus erythematosus profundus (lupus panniculitis). J Am Acad Dermatol 2007;56:643-647.
- 2 Magro CM, Morrison C, Porcu P. Atypical lymphocytic lobular panniculitis: a clonal subcutaneous T-cell dyscrasia. Journal of Cutaneous Pathology 2008; 35:947-954.
- 3 Magro CM, Crowson AN, Soleymani AD, Shendrik I. Atypical lymphocytic lobular panniculitis. J Cutan Pathol 2004;31:300-306.
- 4 Magro CM, Crowson AN, Kovatich AJ, Burns F. Lupus profundus, indeterminate lymphocytic lobular panniculitis and subcutaneous T-cell lymphoma: a spectrum of subcuticular T-cell lymphoid dyscrasia. J Cutan Pathol 2001;28:235-247.
- 5 Park HS, Choi JW, Kim BK, Cho KH. Lupus Erythematosus Panniculitis: Clinicopathological Immunophenotypic, and Molecular Studies. Am J Dermatopathol 2010;32(1)24-30.
- 6 Pincus L, LeBoit P, McCalmont T, Ricci R, Buzio C, Fox L, Oliver F, Cerroni L. Subcutaneous Panniculitis-Like T-Cell Lymphoma with Overlapping Clinicopathologic Features of Lupus Erythematosus: Coexistence of 2 Entities? Am J Dermatopathol 2009;31(6):520-526.
- 7 Willemze R, Jansen PM, Cerroni L, Emilio B, et al. Subcutaneous panniculitis-like T-cell lymphoma: definition, classification, and prognostic factors: an EORTC Cutaneous Lymphoma Group Study of 83 cases. Blood 2008;111(2)838-845.