

## Importance of Obtaining a Detailed Medical History in Diagnosing Emphysematous Cystitis

Jeremy K. Selley DO  
*Lehigh Valley Health Network*

Bryan G. Kane MD  
*Lehigh Valley Health Network, bryan.kane@lvhn.org*

Kathleen E. Kane MD  
*Lehigh Valley Health Network, kathleen\_e.kane@lvhn.org*

Follow this and additional works at: <https://scholarlyworks.lvhn.org/emergency-medicine>



Part of the [Emergency Medicine Commons](#)

---

### Published In/Presented At

Selley, J. K., Kane, B. G., & Kane, K. E. (2010). Importance of obtaining a detailed medical history in diagnosing emphysematous cystitis. *The Journal Of The American Osteopathic Association*, 110(2), 91-94.

This Article is brought to you for free and open access by LVHN Scholarly Works. It has been accepted for inclusion in LVHN Scholarly Works by an authorized administrator. For more information, please contact [LibraryServices@lvhn.org](mailto:LibraryServices@lvhn.org).

## Importance of Obtaining a Detailed Medical History in Diagnosing Emphysematous Cystitis

Jeremy K. Selley, DO  
 Bryan G. Kane, MD  
 Kathleen E. Kane, MD

**Pneumaturia has long been known to be the characteristic pathognomonic finding in emphysematous cystitis. However, its history is often difficult to elicit. Imaging studies are diagnostic in the majority of emphysematous cystitis cases described in the literature. The authors present a unique case in which the patient did not admit having pneumaturia until detailed questioning about her medical history was completed after diagnostic imaging. Had an earlier and more thorough medical history been conducted, the patient's diagnosis would have been achieved several months earlier, before presentation to the emergency department, as described in the present case. Early diagnosis is vital to decrease the morbidity and mortality associated with emphysematous cystitis.**

*J Am Osteopath Assoc.* 2010;110(2):91-94

**E**mphysematous cystitis is an infection of the bladder wall and surrounding tissues. The presentation of this condition is similar to that of uncomplicated cystitis—characterized by urinary frequency and urgency, dysuria, nocturia, gross hematuria, and abdominal pain—with one pathognomonic exception.<sup>1</sup> The unique and defining characteristic of emphysematous cystitis is pneumaturia, caused by gas formation in the infected tissues. Some patients may not recognize pneumaturia, and other patients may be reluctant to acknowledge it. As such, the diagnosis of emphysematous cystitis has evolved from a clinical procedure to largely a radiographic procedure.

Emphysematous cystitis occurs predominately in women, with a median age of onset of 66 years.<sup>2</sup> More than two-thirds of all emphysematous cystitis infections are caused by

*Escherichia coli*, with the remaining cases caused by *Klebsiella pneumoniae*, *Clostridium* spp, and *Enterobacter* spp.<sup>2</sup> Common predisposing factors for development of emphysematous cystitis are similar to those of uncomplicated cystitis, though factors potentially leading to emphysematous cystitis also include diabetes mellitus.<sup>2,3</sup>

Successful management of emphysematous cystitis requires—first and foremost—early diagnosis, followed by the initiation of broad-spectrum intravenous antibiotics, strict glucose control, and urinary drainage.<sup>4</sup> Patients who do not respond to antibiotics or who have necrotizing tissue may require surgical intervention.<sup>5</sup> Failure to recognize emphysematous cystitis early in the course of the disease contributes to the 20% mortality rate of this condition.<sup>6</sup>

### Report of Case

The patient in the present case was a white woman aged 44 years who presented to a hospital's emergency department with intractable left hip pain, which had been increasing in severity during the preceding 6 weeks. The pain was not associated with movement or weight bearing. The patient reported that the pain radiated down her left leg, and she complained of left leg weakness. She denied having back pain, fevers, chills, or loss of bowel or bladder control. The patient was unable to recall experiencing trauma of any kind.

The patient had sought care 4 weeks previously for her pain. During a brief hospitalization at that time, she had normal results on lumbar magnetic resonance imaging, and she was given oral analgesia before being discharged.

The patient's medical history was remarkable for Addison's disease, type 1 diabetes mellitus, gastroparesis, hypothyroidism (resulting from radioiodine treatment for Grave's disease), and an unspecified blood-clotting disorder (resulting in the formation of 14 clots in her left subclavian vein). Her surgical history included removal of two cysts from her left ovary. The patient's family medical history was remarkable for Addison's disease, diabetes mellitus, thyroid disease, and transient ischemic attack.

The patient's outpatient medications included insulin (70% insulin isophane, 30% regular human insulin), fludrocortisone, hydrocortisone, levothyroxine sodium, metoclopramide hydrochloride, pantoprazole sodium, warfarin sodium, multivitamins, and ibuprofen as needed. She was

From the Department of Emergency Medicine at Lehigh Valley Health Network in Allentown and Bethlehem, Pennsylvania.

**Financial Disclosures:** None reported.

Address correspondence to Jeremy K. Selley, DO, Department of Emergency Medicine, Lehigh Valley Health Network, Fifth-Floor Residency Suite, 2545 Schoenersville Rd, Bethlehem, PA 18017-7300.

E-mail: jselley78@hotmail.com

Submitted April 3, 2009; revision received June 2, 2009; accepted June 6, 2009.

## CASE REPORT

not taking herbal supplements and denied using alcohol, tobacco, or illicit drugs. She reported hypersensitivity to codeine.

A review of the patient's systems was notable for complaints of urinary frequency, but no urgency, dysuria, or abdominal pain. The patient also noted mild nausea and occasional diarrhea. She denied having weight loss or weight gain.

### Examination Findings

Initial vital signs of the patient included a low blood pressure of 87/40 mm Hg, a heart rate of 84 beats per minute, a respiratory rate of 18 breaths per minute, a body temperature of 97.0°F (36.1°C), and an oxygen saturation of 99% with room air (Table). The patient was alert and oriented. Head and neck examinations yielded normal results. The cardiovascular examination showed regular S1 and S2 sounds, with no murmurs, gallops, or rubs.

**Table**  
Examination and Laboratory Findings  
of Patient at Presentation

Component	Value
<b>■ Examination Findings</b>	
□ Blood pressure, mm Hg	87/40
□ Respiratory rate, number/min	18
□ Heart rate, beats/min	84
□ Oxygen saturation, %	99
□ Body temperature, °F (°C)	97.0 (36.1)
<b>■ Laboratory Findings</b>	
□ Blood count	
– Hemocrit, %	32.3
– Hemoglobin, g/dL	10.6
– Platelets, × 10 <sup>3</sup> /mL	509
– White blood cells, × 10 <sup>3</sup> /mL	6.3
□ Chemistry profile	
– Bicarbonate, mEq/L	23
– Blood urea nitrogen, mg/dL	34
– Chloride, mEq/L	94
– Creatinine, mg/dL	1.7
– Glucose (random), mg/dL	367
– Sodium, mEq/L	132
□ Urinalysis	
– Blood (nonspecific), mg/dL	>1
– Glucose (random), mg/dL	>1000
– Ketone, mg/dL	15
– pH	5.0
– Protein (nonspecific), mg/dL	100-200
– Specific gravity	1.022
□ Other	
– International normalized ratio	2.2
– Partial thromboplastin time, s	38.2
– Prothrombin time, s	25.1

The patient's lungs were clear to auscultation bilaterally. No rales, wheezes, or rhonchi were heard. Her abdomen was soft and nontender. Most notably, no hepatosplenomegaly or costovertebral angle tenderness was found. Normal bowel sounds were noted. Rectal examination demonstrated normal tone, with guaiac-negative stool results and no perianal anesthesia.

The patient had good pulses in all limbs, without clubbing, cyanosis, or edema. Her skin was without rashes, lesions, or excoriations.

Cranial nerve examination yielded normal results. The patient had 5/5 muscle strength in all extremities. Her sensation to light touch was intact, and she had normal deep tendon reflexes. Examination of the patient's back showed no midline tenderness to palpation over her lumbar vertebrae or sacrum.

The patient's left hip range of motion was normal. Results of her straight leg test were negative bilaterally. Of note, palpation along the upper shaft of the left femur demonstrated tenderness.

In an osteopathic diagnostic examination, positions of the L2 to L4 vertebrae were found to be neutral, rotated right, and sidebent left. No Chapman reflex points or tender points were located.

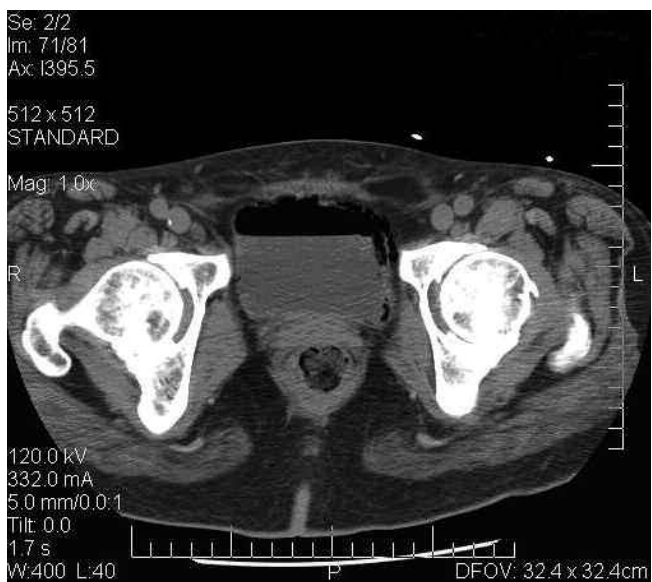
### Laboratory Findings

The patient's laboratory results revealed a normal white blood cell count ( $6.3 \times 10^3$ /mL); an elevated platelet count ( $509 \times 10^3$ /mL); and a depressed hemoglobin level (10.6 g/dL) and hematocrit concentration (32.3%) (Table). The chemistry profile showed depressed levels of sodium (132 mEq/L) and chloride (94 mEq/L); a normal level of bicarbonate (23 mEq/L); elevated levels of blood urea nitrogen (34 mg/dL) and creatinine (1.7 mg/dL); and a markedly elevated nonfasting blood glucose level (367 mg/dL). The patient's prothrombin time and partial thromboplastin time were elevated at 25.1 seconds and 38.2 seconds, respectively. The international normalized ratio was elevated at 2.2.

Urinalysis results showed a pH of 5.0; a normal specific gravity of 1.022; and abnormal findings of glucose (>1000 mg/dL); ketone (15 mg/dL); nonspecific blood (>1 mg/dL); and nonspecific protein (100-200 mg/dL) (Table). Nitrate test results were positive, and leukocyte esterase test results were negative. Urine microscopy showed—per high power field—no white blood cells, red blood cells too numerous to count, more than 2 bacterial cells, and between 1 and 5 epithelial cells.

### Diagnosis

After laboratory results were evaluated, a diagnostic computed tomography (CT) examination was ordered (Figure). Results of the CT imaging revealed infection-caused emphysema of the bladder wall and surrounding tissues, with gas for-



**Figure.** Computed tomography scan of the hip region of the patient, a woman aged 44 years with increasingly severe intractable left hip pain. The image reveals gas formation in the bladder (center) and surrounding tissues, indicative of pneumaturia—the diagnostic characteristic of emphysematous cystitis.

mation in the infected tissues. The images established the diagnosis of emphysematous cystitis.

Secondary questioning of the patient—prompted by the CT images—resulted in the patient acknowledging that she had been experiencing pneumaturia since her pain started 6 weeks previously. However, she had not told anyone, including her husband, about the pneumaturia, because she felt embarrassed by it.

### Interventions

During the patient's emergency department evaluation, she received multiple narcotic administrations for pain relief and 2 L of isotonic fluids intravenously. After diagnosis, the patient was placed on intravenous piperacillin sodium/tazobactam sodium for broad antibiotic coverage, as well as dexamethasone for prevention of Addisonian crisis and for possible septic shock. She was then admitted to the hospital.

Results from the laboratory urine culture, obtained 2 days after admission, were positive for *E. coli* that was most sensitive to amoxicillin/clavulanate. Based on this finding, the patient was switched to oral amoxicillin/clavulanate antibiotics (875/125 mg twice daily for 4 weeks). She was discharged 3 days after admission to continue the 4-week antibiotic course.

### Results and Follow-Up

The patient's pain gradually resolved during the first week after discharge. Follow-up diagnostic CT imaging 2 weeks

after discharge demonstrated resolution of the bladder wall emphysema.

In retrospect—based on the clinical course of this patient—her low presenting blood pressure was determined to be related to chronic adrenal insufficiency rather than to sepsis.

### Comment

Emphysematous cystitis was initially described in 1671 in a man who “passed wind through the urethra.”<sup>5</sup> A 2007 review of the literature by Thomas et al<sup>2</sup> found only 135 cases of emphysematous cystitis documented between 1956 and 2006.

The cause of progression from an uncomplicated cystitis to an emphysematous cystitis—as well as the mechanism of gas production in emphysematous cystitis—remains unknown.<sup>7</sup> The combination of bacterial alcohol fermentation, resulting in increased glucose levels, and impaired tissue perfusion has been proposed for the mechanism of gas production.<sup>7,8</sup> However, this hypothesis has not been confirmed.

Research has shown that, in patients with emphysematous cystitis, gas-forming bacteria produce enzymes that convert acids into carbon dioxide when the pH level reaches 6.0 or lower.<sup>6</sup> In addition, vascular compromise and damage from long-term glycosylation in diabetes mellitus—a predisposing factor for emphysematous cystitis—slow the transport of catabolic products, leading to gas accumulation.<sup>2</sup> In patients without diabetes mellitus, albumin has been hypothesized as a substrate for gas formation.<sup>9</sup> In emphysematous cystitis, gas formation can occur not only in the bladder but also in the prostate, periurethral tissue, and scrotum.<sup>10</sup>

Emphysematous cystitis can occur in men. However, for unknown reasons, the disease occurs predominately in women, typically during the sixth decade of life.<sup>2,10</sup> Patients with chronic urinary tract infections, indwelling urethral catheters, urinary tract outlet obstruction, or neurogenic bladders are also predisposed to the development of emphysematous cystitis.<sup>2,3</sup>

For patients with emphysematous cystitis, early diagnosis is crucial to successful treatment. After diagnosis, patients should receive broad-spectrum intravenous antibiotics—with sensitivities tapering—and strict glucose control and urinary drainage.<sup>4</sup> Patients who do not respond to antibiotics or who have necrotizing tissue might require cystectomy or surgical debridement of the necrotizing tissue.<sup>5</sup> Fortunately, in the case described in the present article, the patient responded to antibiotics rapidly and needed no surgical intervention, and she was asymptomatic after 2 weeks.

The diagnosis of emphysematous cystitis remains largely a radiographic process. Abdominal plain radiographic films are used in the diagnosis of 84% of reported cases. These images reveal a curvilinear area of radiolucency—often described as having a “cobblestone” or “beaded neck” appearance—delineating the bladder wall with or without intraluminal air.<sup>2,9</sup> Emphysematous cystitis is easily identified by CT scans, but the more vital role of CT imaging is defining the extent of the

## CASE REPORT

disease. For patients with diabetes mellitus, abdominal pain, and hematuria who have symptoms of urinary tract infections, Grupper et al<sup>6</sup> suggests using an abdominal plain radiographic film in initial screening for emphysematous cystitis. If results of this screening are positive or if there are concerns regarding severe disease, a CT scan should be performed.<sup>6</sup>

Although the patient in the present case was ultimately diagnosed as having emphysematous cystitis and successfully treated, the most intriguing aspect of the case was the patient's medical history. The patient's presenting complaint was intractable, with progressive left hip pain during the previous 6 weeks. She had an extensive medical history for uncontrolled diabetes mellitus and corticosteroid use for Addison's disease. Both of these conditions are associated with avascular necrosis of the femoral head and with emphysematous cystitis.

The fulcrum of the present report, as in all cases of emphysematous cystitis, was the patient's history of pneumaturia. In her clinical encounters elsewhere before presenting to the emergency room, the patient either never volunteered that she had pneumaturia or was never asked about it. If this condition had been correctly identified in previous clinical encounters, the use of diagnostic imaging could have been minimized. Obtaining a more detailed medical history of the patient could have reduced the delay in correct diagnosis.

To know is to ask, and to ask is to diagnose. The correct diagnosis of emphysematous cystitis was available to the patient's clinicians throughout the progression of her illness—had the proper questions been asked of her in a thorough medical history.

## Conclusion

Knowledge of emphysematous cystitis and its risk factors are keys to increasing clinical suspicion for this condition. Increased suspicion should lead physicians to obtain more detailed medical histories of patients and to refer the patients for more appropriate imaging screening. In this manner, delays in diagnosis could be reduced, likely leading to more successful treatment.

## References

1. Mokabberi R, Ravakhah K. Emphysematous urinary tract infections: diagnosis, treatment and survival (case review series). *Am J Med Sci*. 2007;333(2):111-116.
2. Thomas AA, Lane BR, Thomas AZ, Remer EM, Campbell SC, Shoskes DA. Emphysematous cystitis: a review of 135 cases [review]. *BJU Int*. 2007;100(1):17-20.
3. Quint HJ, Drach GW, Rappaport WD, Hoffmann CJ. Emphysematous cystitis: a review of the spectrum of disease. *J Urol*. 1992;147(1):134-137.
4. Stapleton A. Urinary tract infections in patients with diabetes [review]. *Am J Med*. 2002;113(suppl 1A):80S-84S.
5. Perlmutter AE, Mastromichaelis M, Zaslau S. Emphysematous cystitis: a case report and literature review. *W V Med J*. 2004;100(6):232-233.
6. Grupper M, Kravtsov A, Potasman I. Emphysematous cystitis: illustrative case report and review of the literature. *Medicine (Baltimore)*. 2007;86(1):47-53.
7. Huang JJ, Chen KW, Ruaan MK. Mixed acid fermentation of glucose as a mechanism of emphysematous urinary tract infection. *J Urol*. 1991;146(1):148-151.
8. Yang WH, Shen NC. Gas-forming infection of the urinary tract: an investigation of fermentation as a mechanism. *J Urol*. 1990;143(5):960-964.
9. Hawtrey CE, Williams JJ, Schmidt JD. Cystitis emphysematosa. *Urology*. 1974;3(5):612-614.
10. Patel NP, Lavengood RW, Fernandes M, Ward JN, Walczak MP. Gas-forming infections in genitourinary tract. *Urology*. 1992;39(4):341-345.

### Call for Peer Reviewers

JAOA—*The Journal of the American Osteopathic Association* is looking for physicians, basic scientists, and others in the biomedical professions who are interested in serving as peer reviewers.

Each prospective peer reviewer should send a letter and curriculum vitae to AOA Editor in Chief Gilbert E. D'Alonzo, Jr, DO, at [jaoa@osteopathic.org](mailto:jaoa@osteopathic.org). Applicants should describe in their letters why they are interested in becoming peer reviewers for the JAOA and indicate their areas of expertise or interest.

For more information, visit <http://www.jaoa.org/misc/peer.html>.