

Laparoscopic Repair of Incarcerated Obturator Hernia

Danielle Press MD
Lehigh Valley Health Network

Dale A. Dangleben MD
Lehigh Valley Health Network, Dale_A.Dangleben@lvhn.org

Follow this and additional works at: <https://scholarlyworks.lvhn.org/surgery>



Part of the [Other Medical Specialties Commons](#), and the [Surgery Commons](#)

Let us know how access to this document benefits you

Published In/Presented At

Press, D., & Dangleben, D. A. (2011). Laparoscopic Repair of Incarcerated Obturator Hernia. *LVHN Scholarly Works*. Retrieved from <https://scholarlyworks.lvhn.org/surgery/17>

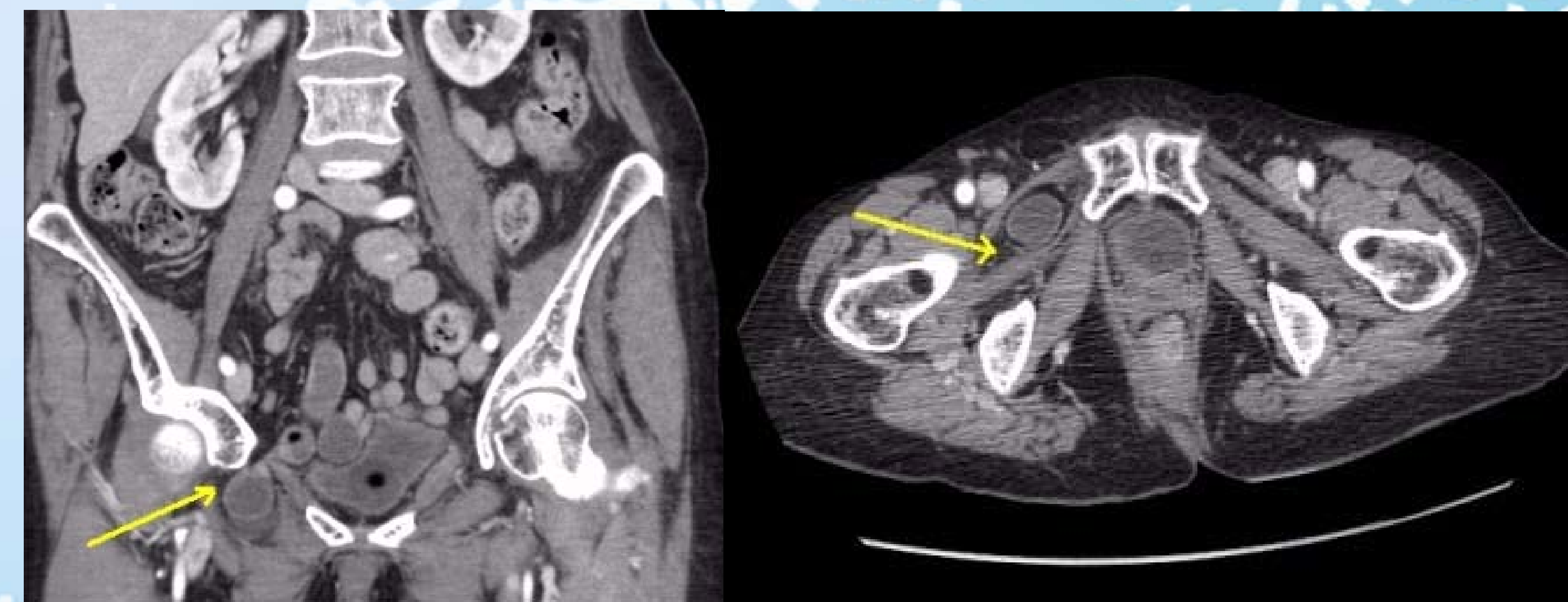This Poster is brought to you for free and open access by LVHN Scholarly Works. It has been accepted for inclusion in LVHN Scholarly Works by an authorized administrator. For more information, please contact LibraryServices@lvhn.org.

Laparoscopic Repair of Incarcerated Obturator Hernia

Danielle Press, MD; Dale A. Dangleben, MD
Lehigh Valley Health Network, Allentown, Pennsylvania

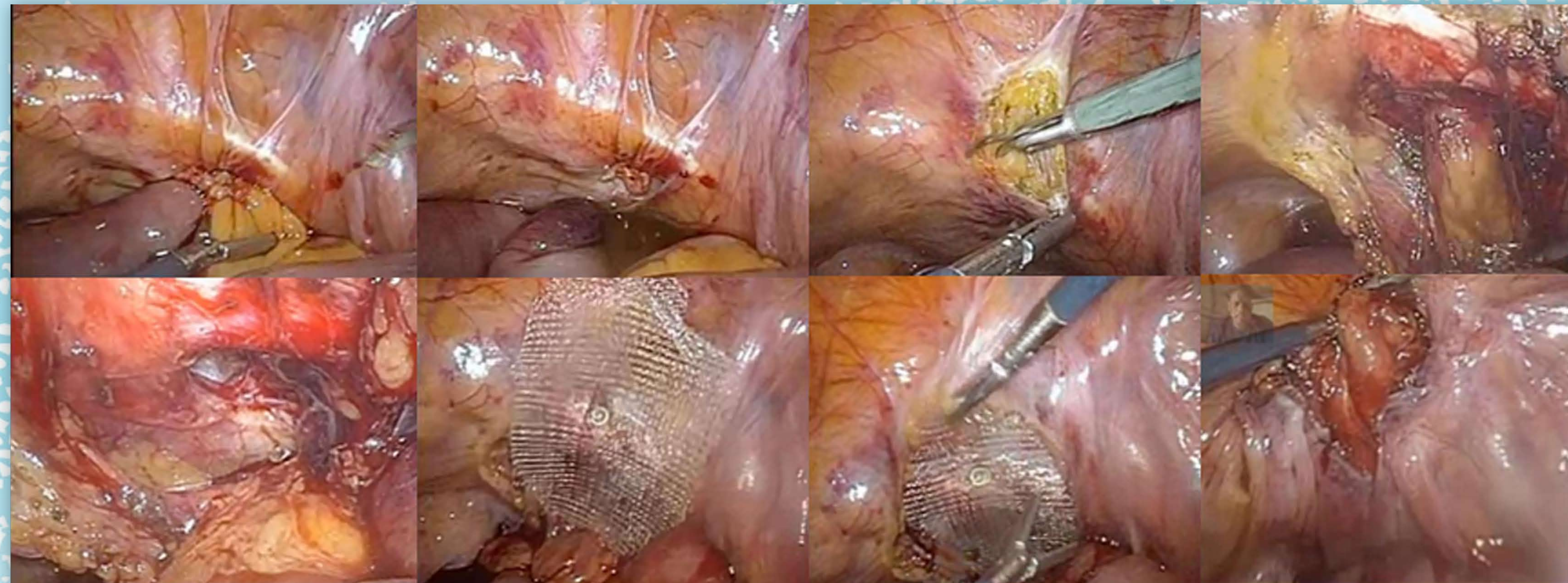
CASE REPORT:

We are presenting a case of an 83 year-old woman who presented with lower abdominal pain. A CT scan of the abdomen and pelvis revealed an obturator hernia. The patient was taken to the operating room and underwent a laparoscopic repair of incarcerated obturator hernia.



INTRODUCTION:

Obturator hernia is a rare hernia in which there is protrusion of intra-abdominal contents through the obturator foramen. Obturator hernias most commonly present as small bowel obstruction and are more common in females.



CONCLUSION:

An obturator hernia is typically approached via a lower midline transperitoneal approach, lower midline extra-peritoneal approach, or anterior thigh approach. However, a laparoscopic approach proved to be a beneficial alternative technique for treatment of this diagnosis.