

Glucocorticoid-Remediable Aldosteronism: An Uncommon and Often Overlooked Cause of Adrenal Hypertension

Sindhu Bhat MD
Lehigh Valley Health Network

Larry N. Merkle MD
Lehigh Valley Health Network

Follow this and additional works at: <https://scholarlyworks.lvhn.org/medicine>



Part of the [Medical Sciences Commons](#)

Let us know how access to this document benefits you

Published In/Presented At

Bhat, S., & Merkle, L. (2010). *Glucocorticoid-remediable aldosteronism: An uncommon and often overlooked cause of adrenal hypertension*. Poster presentation.

This Poster is brought to you for free and open access by LVHN Scholarly Works. It has been accepted for inclusion in LVHN Scholarly Works by an authorized administrator. For more information, please contact LibraryServices@lvhn.org.

Glucocorticoid-Remediable Aldosteronism: An Uncommon and Often Overlooked Cause of Adrenal Hypertension

Sindhu Bhat, MD; Larry N. Merkle, MD
Lehigh Valley Health Network, Allentown, Pennsylvania

Introduction:

Glucocorticoid-Remediable Aldosteronism (GRA) is a rare form of hyperaldosteronism. Early recognition of this problem in a hypertensive patient not responding to the usual hypertensive medications can help prevent serious complications of hypertension.

Case Presentation:

- A 66 year old male with a long standing history of hypertension which was apparently well controlled initially, recently had accelerated hypertension not responding to multiple medications which included Bystolic, Amlodipine, Diovan and Minoxidil.
- His BP was over 180s/100s and at times was in the 200s/100s.
- His past medical history included Hypercholesterolemia, Diabetes and Hypertension.
- His father had Hypertension and had died of a stroke in his early 60s and his son has Hypertension.
- Labs: Metanephrines and Normetanephrines which were high. {Metanephrine-318mcg/24h (Normal 90-315), Normetanephrine-1080mcg/24h (Normal 122-676) and Total Metanephrines-1398mcg/24h (Normal 224-832)}. He also had hypokalemia and was on potassium replacement at home. Plasma Aldosterone level was 17ng/dl which is in the high normal range, renin was < 0.5ng/ml/hr which is low and ACTH was 11pg/ml which was normal. His urine free cortisol was 17 mcg/h which was normal.
- CT scan of abdomen showed a right adrenal nodular mass and left adrenal hyperplasia.

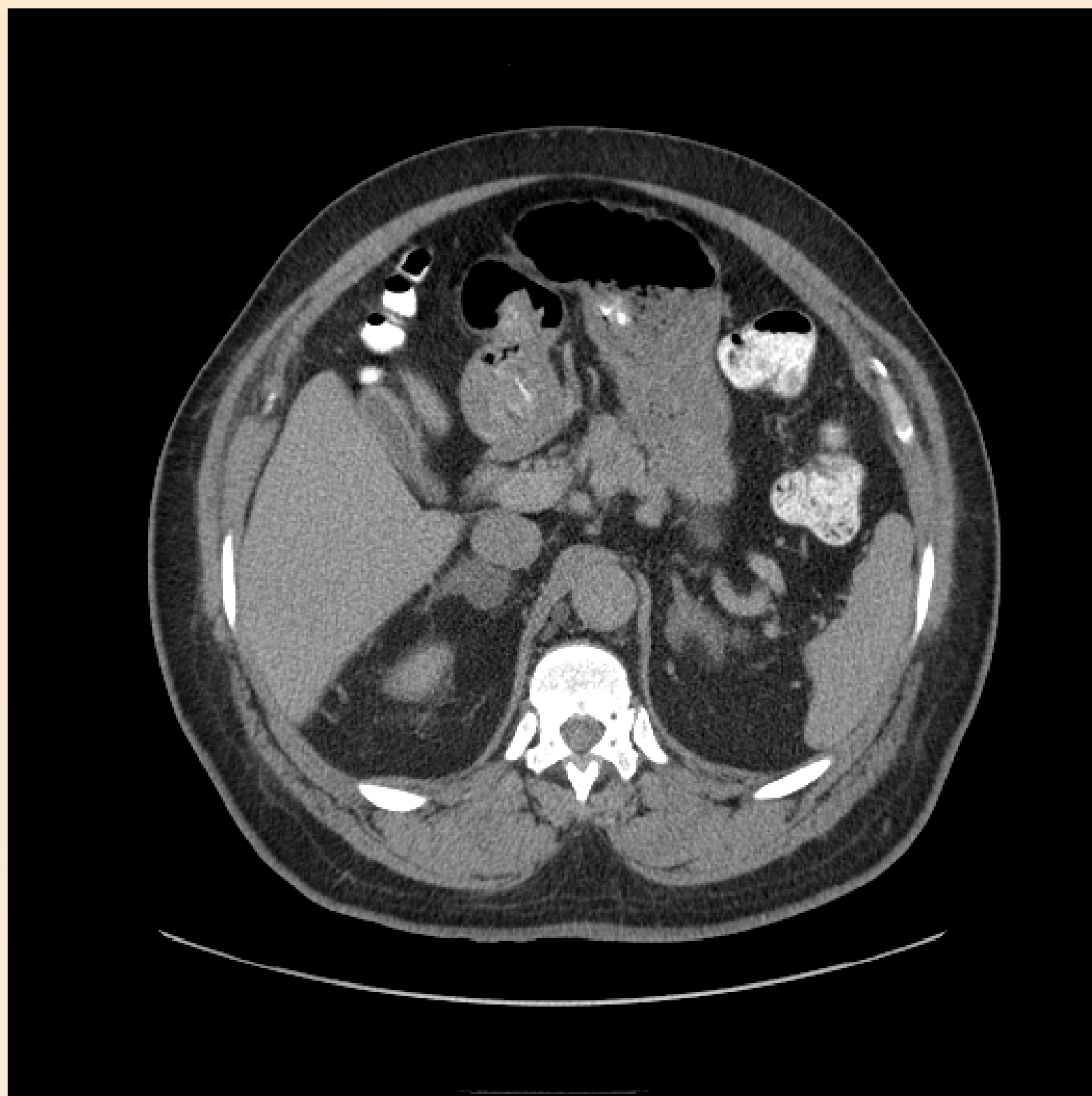

Figure: CT of Abdomen with contrast showing right adrenal nodular lesion and left adrenal limb thickening representing hyperplasia.

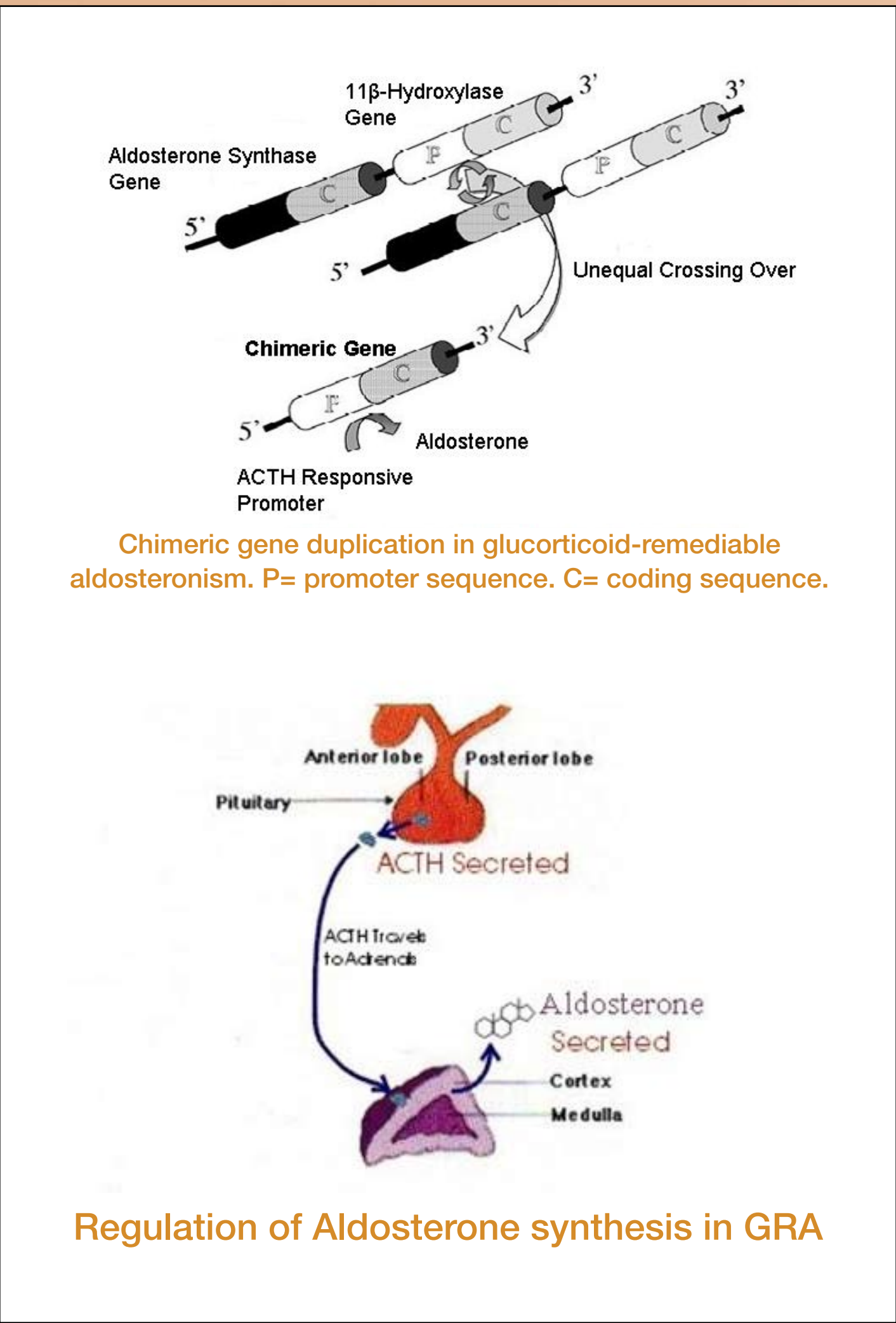
Intervention and Treatment:

- Right adrenalectomy was done for a possible Pheochromocytoma vs Primary Hyperaldosteronism.
- Histopathology showed diffuse micronodular and macronodular adrenal hyperplasia and the adrenal medulla was normal.
- There was little improvement in blood pressure post-op and the hypokalemia persisted.
- Post-op Aldosterone level was 39ng/dl and 27ng/dl on 2 separate readings 2 months after surgery.
- After reviewing the literature it was suspected that the patient had underlying Glucocorticoid-Remediable Aldosteronism. He was then started on Dexamethasone 2mg which promptly improved his BP and resolved his Hypokalemia and Aldosterone level was 11ng/dl 1 month after starting Dexamethasone.
- Patient's BP is currently 130s/70s and his medications include Dexamethasone 1mg, Aspirin, Simvastatin, Bystolic 10mg every other day and Aldactone 100mg daily.
- Patient is currently awaiting genetic testing and subsequently an MRA for screening of intracranial aneurysms.

Discussion:

- There are few published case reports of patients with GRA.
- It is an autosomal dominant form of aldosteronism which results from a chimeric gene for the enzyme aldosterone synthase.
- It has been shown to be caused by a hybrid gene mutation formed by a cross-over of genetic material between the ACTH-responsive regulatory portion of the 11b-hydroxylase (CYP11B1) gene and the coding region of the aldosterone synthase (CYP11B2) gene.
- ACTH stimulates the expression and secretion of aldosterone in the Zona Fasciculata, which is normally controlled by the renin axis.
- Plasma aldosterone is elevated and plasma renin activity is suppressed, but the aldosterone-renin ratio is typically not as high as with primary hyperaldosteronism caused by an aldosterone-producing adenoma.

- It is also characterised by the production of two rare steroids, 18hydroxycortisol and 18oxocortisol.
- Aldosterone suppression by dexamethasone, and high 18-hydroxycortisol and 18-oxocortisol levels are used to differentiate glucocorticoid-remediable aldosteronism (GRA) from other forms of primary aldosteronism. Diagnosis is confirmed by genetic testing.
- Treatment with physiological doses of glucocorticoid will correct the oversecretion of aldosterone by suppressing ACTH and will lower the blood pressure and correct the hypokalemia. Treatment with mineralocorticoid receptor antagonist in these patients may be just as effective.
- Analysis of affected patients has demonstrated a high prevalence of early cerebral hemorrhage, largely as a result of aneurysms.



Conclusion:

Glucocorticoid-Remediable Aldosteronism is a fairly rare cause of Hyperaldosteronism which should be considered in the differential diagnosis of secondary causes of hypertension especially when there is a strong family history of severe refractory hypertension.

References:

- Rich GM; Ulick S; Cook S; et al. Glucocorticoid-remediable aldosteronism in a large kindred: clinical spectrum and diagnosis using a characteristic biochemical phenotype. Ann Intern Med 1992 May 15;116(10):813-20.
- Mulatero P; Veglio F; Pilon C; et al. Diagnosis of glucocorticoid-remediable aldosteronism in primary aldosteronism: aldosterone response to dexamethasone and long polymerase chain reaction for chimeric gene. J Clin Endocrinol Metab 1998 Jul;83(7):2573-5.