

Case report: response to the ERK1/2 inhibitor ulixertinib in BRAF D594G cutaneous melanoma.

Zachary Wolfe MD

Lehigh Valley Health Network, zachary.wolfe@lvhn.org

Julie C Friedland

Sarah Ginn

Aaron U. Blackham MD

Lehigh Valley Health Network, Aaron.Blackham@lvhn.org

Lauren Demberger PA-C

Lehigh Valley Health Network, lauren.demberger@lvhn.org

See next page for additional authors

Follow this and additional works at: <https://scholarlyworks.lvhn.org/hematology-medical-oncology-division>



Part of the [Medicine and Health Sciences Commons](#)

Published In/Presented At

Wolfe Z, Friedland JC, Ginn S, Blackham A, Demberger L, Horton M, McIntosh A, Sheikh H, Box J, Knoerzer D, Federowicz B, Stuhlmiller TJ, Shapiro M, Nair S. Case report: response to the ERK1/2 inhibitor ulixertinib in BRAF D594G cutaneous melanoma. *Melanoma Res.* 2022 May 12. doi: 10.1097/CMR.0000000000000830. Epub ahead of print. PMID: 35551160.

This Article is brought to you for free and open access by LVHN Scholarly Works. It has been accepted for inclusion in LVHN Scholarly Works by an authorized administrator. For more information, please contact LibraryServices@lvhn.org.

Authors

Zachary Wolfe MD; Julie C Friedland; Sarah Ginn; Aaron U. Blackham MD; Lauren Demberger PA-C; Morgan M. Horton BSN, RN, CCRC; Alyson McIntosh MD; Hina A. Sheikh MD; Jessica Box; Deborah Knoerzer; Bryan Federowicz; Timothy J Stuhlmiller; Mark Shapiro; and Suresh G. Nair MD

Case report: response to the ERK1/2 inhibitor ulixertinib in BRAF D594G cutaneous melanoma

Zachary Wolfe^a, Julie C. Friedland^b, Sarah Ginn^b, Aaron Blackham^c, Lauren Demberger^a, Morgan Horton^a, Alyson McIntosh^d, Hina Sheikh^e, Jessica Box^f, Deborah Knoerzer^f, Bryan Federowicz^b, Timothy J. Stuhlmiller^b, Mark Shapiro^b and Suresh Nair^a

Melanoma is characterized by oncogenic mutations in pathways regulating cell growth, proliferation, and metabolism. Greater than 80% of primary melanoma cases harbor aberrant activation of the mitogen-activated protein kinase kinase/extracellular-signal-regulated kinase (MEK/ERK) pathway, with oncogenic mutations in BRAF, most notably BRAF V600E, being the most common. Significant progress has been made in BRAF-mutant melanoma using BRAF and MEK inhibitors; however, non-V600 BRAF mutations remain a challenge with limited treatment options. We report the case of an individual diagnosed with stage III BRAF D594G-mutant melanoma who experienced an extraordinary response to the ERK1/2 inhibitor ulixertinib as fourth-line therapy. Ulixertinib was obtained via an intermediate expanded access protocol with unique flexibility to permit

both single-agent and combination treatments, dose adjustments, breaks in treatment to undergo surgery, and long-term preventive treatment following surgical resection offering this patient the potential for curative treatment. *Melanoma Res* 32: 295–298 Copyright © 2022 The Author(s). Published by Wolters Kluwer Health, Inc.

Melanoma Research 2022, 32:295–298

Keywords: immunotherapy, melanoma, targeted therapy

^aDepartment of Hematology/Oncology, Lehigh Valley Topper Cancer Institute, Allentown, Pennsylvania, ^bCures, Inc., Oakland, California, Departments of ^cSurgical Oncology, ^dRadiation Oncology, and ^ePathology, Lehigh Valley Topper Cancer Institute, Allentown, Pennsylvania and ^fBioMed Valley Discoveries, Kansas City, Missouri, USA

Correspondence to Zachary Wolfe, MD, Lehigh Valley Topper Cancer Institute, 1240 S. Cedar Crest Blvd., Suite 401 Allentown, 18103 PA, USA
Tel: +1 610 402 7880; e-mail: zachary.wolfe@lvhn.org

Received 15 February 2022 Accepted 7 April 2022

Introduction

Melanoma is associated with aberrant activation of the mitogen-activated protein kinase kinase/extracellular-signal-regulated kinase (MEK/ERK) pathway in more than 80% of cases [1]. Mutations in the BRAF gene are the most common mutations and reported in approximately 50% of melanoma cases [1–3]. Although most BRAF mutations occur at codon 600 (most commonly V600E), non-V600 mutations occur in a low percentage of patients [3].

There has been significant development in targeted therapies for BRAF mutations, including the selective inhibitors of BRAF V600-mutant kinase dabrafenib and vemurafenib, and inhibitors of the downstream kinase MEK such as cobimetinib and trametinib. As a result, numerous landmark studies have reported dramatic improvements in both overall and progression-free survival in patients with melanoma harboring BRAF V600 mutations [4–6]. Given these advances, molecular testing

for BRAF mutations in advanced melanoma patients has become standard practice and is recommended by the National Comprehensive Cancer Network and European Society for Medical Oncology. However, despite significant progress in targeting BRAF V600 mutations, options for atypical, non-V600 mutations are severely limited.

BRAF D594G is a class 3 BRAF mutation resulting in a kinase-dead, catalytically inactive BRAF protein that dimerizes with the CRAF protein to result in hyperactivation of ERK [7,8]. BRAF D594G mutations have been shown to confer sensitivity to RAF inhibitors, as well as to MEK inhibitors such as trametinib [9]. Indeed, the phase 2 NCI-MATCH trial reported prolonged stable disease in a BRAF D594G-mutant lung cancer patient treated with trametinib [10]. Here, we present the first case, to our knowledge, of a patient with advanced melanoma harboring the BRAF D594G mutation who has been treated successfully with an ERK inhibitor. Notably, this patient accessed ulixertinib via an expanded access program (NCT04566393) as she was ineligible for active clinical trials at the time. Safety and outcomes data were collected and structured according to an observational research protocol (XCELSIOR, NCT03793088).

This is an open-access article distributed under the terms of the Creative Commons Attribution-Non Commercial-No Derivatives License 4.0 (CCBY-NC-ND), where it is permissible to download and share the work provided it is properly cited. The work cannot be changed in any way or used commercially without permission from the journal.

Presentation of case

A 43-year-old female patient was diagnosed with pT1a melanoma of the left lateral lower back. Following excision of the melanoma, she was followed for 4 years without incident until she developed left axillary adenopathy measuring 4.7 cm. Biopsy of the adenopathy revealed melanoma. A PET/computed tomography showed FDG-avid lymphadenopathy in the left axillary and subpectoral lymph nodes but no other sites of disease. The disease was deemed unresectable due to axillary vein involvement and muscle wall attachment. MRI of the brain was negative for intracranial metastases.

Molecular profiling of the biopsied tissue through Strata, Ann Arbor, Michigan, USA (<https://stratadx.com/>) identified the BRAF D594G mutation, a TERT promoter mutation, an inactivating PTEN mutation, and two mutations of unknown significance in MEN1 and CDH20. Microsatellite status was stable and tumor mutational burden was low (4 muts/Mb).

Treatment was initiated with nivolumab 1 mg/kg and ipilimumab 3 mg/kg every 21 days. The patient developed grade 4 immune-related colitis. Due to grade 4 toxicity, immunotherapy was not resumed, and the patient was started trametinib 2 mg daily given the atypical BRAF mutation. She developed diarrhea and a rash and only remained on this treatment for 1 month without response. Her disease remained isolated to the left axillary and subpectoral lymph nodes but remained unresectable. T-VEC, a genetically modified herpes virus injected directly into lesions, was given in combination with pembrolizumab. Following nine T-VEC treatments and four cycles of pembrolizumab 200 mg every 21 days, imaging showed stable disease in the left axilla and subpectoral region, with the largest dominant node still measuring 4.5 cm.

The patient was then enrolled in an Expanded Access Program for the ERK1/2 inhibitor ulixertinib (NCT04566393). She started single-agent ulixertinib 600 mg twice daily. After 6 days of treatment, she noticed a decrease in the bulkiness of the left axillary lymph nodes. Due to grade 1 mucositis, grade 1 rash, grade 1 diarrhea, and intermittent grade 2 visual floaters, the ulixertinib dose was adjusted numerous times over the course of several weeks and ultimately held for a period of 2 weeks, after which it was resumed at 150 mg twice daily with no further adverse effects.

Imaging after 2 months of ulixertinib showed persistent disease in the left axilla and subpectoral region, again measuring 4.5 cm. However, the nodal mass demonstrated central necrosis and had detached from the chest wall, musculature, and vessels. The disease was deemed resectable. Ulixertinib was held for 1 week before left axillary lymph node dissection with en bloc pectoralis minor muscle resection of levels I, II, and III. Pathology revealed a histologic response to treatment,

with extensive tumoral melanosis and very few preserved tumor cells remaining in two lymph nodes (about 20 cells in each node) (Fig. 1). The patient's disease was deemed high risk for local recurrence based on the bulky disease, and so, she received postoperative radiation to the left axillary lymph node basin (3000 cGy).

Notably, despite the histologic response to treatment, the lymph node size had not changed significantly after treatment with ulixertinib compared with after treatment with T-VEC and pembrolizumab. A biopsy was not performed between these lines of therapy. Therefore, we could not determine how much of the treatment effect was due to immunotherapy versus the ulixertinib. For this reason, she completed 1 year of adjuvant therapy with both pembrolizumab 200 mg every 21 days and ulixertinib 150 mg twice daily. She is currently disease-free 1 year after surgery.

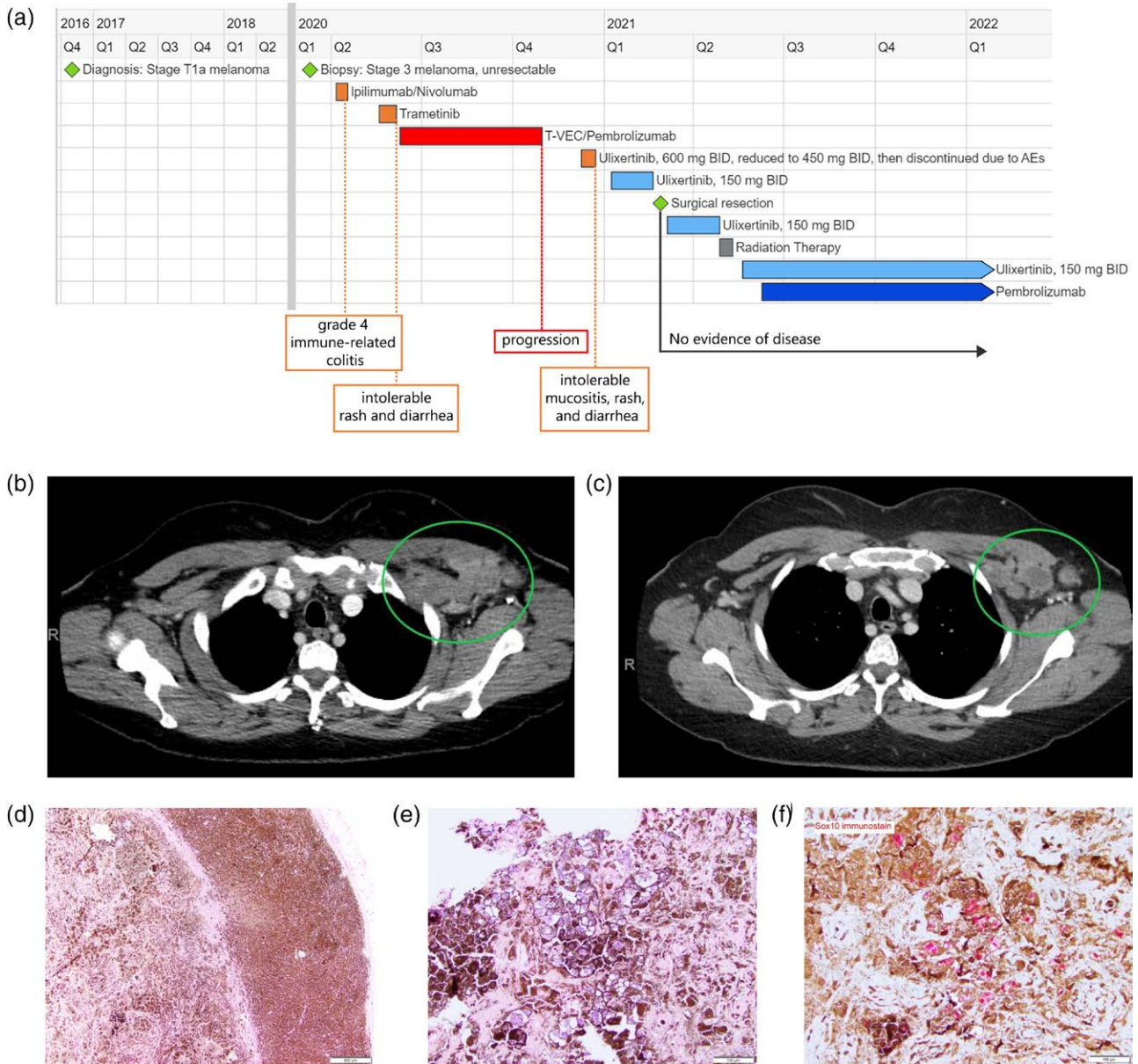
Discussion

This is the first case report demonstrating the use of an ERK1/2 inhibitor in a patient with BRAF-mutant melanoma.

The efficacy of targeted treatments in BRAF-mutant cancers varies, with some patients showing no response and others demonstrating a dramatic response. Moreover, while there has been significant development in options for BRAF V600-mutant tumors, options for atypical mutations outside of BRAF V600 remain limited. This patient's tumor had an atypical BRAF mutation that results in a kinase-dead, catalytically inactive BRAF protein that dimerizes with the CRAF protein to lead to hyperactivation of ERK [7,8]. Her tumor also had a TERT promoter mutation. The combination of BRAF V600E and TERT promoter mutations has been reported in several tumor types and has been correlated with more aggressive disease and poor outcomes [11–13]. BRAF V600E has been shown to signal through the MAPK pathway to promote the formation of the GABPA-GABPB transcriptional complex to upregulate TERT expression in TERT promoter-mutant cells [14,15]. While the combination of the BRAF and TERT mutations leads to a more aggressive phenotype, the effects of this combination on response to therapy remain elusive. BRAF V600E and TERT promoter mutations were associated with better response to BRAF V600E-targeted therapies such as dabrafenib and trametinib in one study but showed a predictive value for treatment failure in a separate study [15,16]. Furthermore, it is unclear how an atypical BRAF mutation fits into this picture, as activation of the MEK/ERK pathway occurs through a mechanism distinct from that of BRAF V600E. Understanding the BRAF-TERT paradigm may prove relevant in understanding a patient's disease and in predicting their therapeutic outcomes.

Ulixertinib (BVD-523) is a highly potent, selective, reversible ERK1/2 inhibitor that has shown antitumor activity in both BRAF- and RAS-mutant preclinical

Fig. 1.



(a) Timeline of anticancer treatment and response. (b) Contrast-enhanced CT image showing size and enhancement of left axillary lymphadenopathy prior to initiation of ulixertinib. (c) Contrast-enhanced CT image showing central necrosis consistent with response to ulixertinib treatment. (d) Low-power exam showing abundant melanosis and macrophages in nodal tissue postulixertinib treatment (magnification 40x). (e) High-power exam showing a focal cluster of viable tumor cells postulixertinib treatment (magnification 200x). (f) High-power exam showing staining for Sox 10 expression (melanoma marker) postulixertinib treatment (magnification 200x). CT, computed tomography.

models [17]. A phase 1 study in patients with advanced solid tumors reported clinical activity of single-agent ulixertinib in both BRAF V600- and non-V600-mutant malignancies, including objective responses in a glioblastoma patient and a lung cancer patient with brain metastases, demonstrating also that ulixertinib penetrates the CNS [18]. Ulixertinib is currently under investigation in multiple phase 1 and phase 2 clinical trials in several different tumor types, including a phase 2 clinical trial

currently enrolling patients with advanced solid tumors harboring atypical (non-V600) BRAF mutations or alterations in MEK1/2 (NCT04488003).

A unique aspect of this patient's care was the flexibility in which the physician was able to treat her with an investigational therapeutic. Under the intermediate expanded access protocol NCT04566393, we were able to make dose adjustments when necessary, pause treatment for

surgery and radiation, and combine ulixertinib with an immunotherapy agent as part of personalized care. Ulixertinib provided a clinically meaningful benefit by rendering her disease resectable, and she currently remains disease-free at 1 year.

Acknowledgements

Conflicts of interest

J.C.F., S.G., B.F., T.J.S., and M.S. are employees of and own stock options of xCures, Inc. J.B. and D.K. are employees of BioMed Valley Discoveries. For the remaining authors, there are no conflicts of interest.

References

- Scolyer RA, Long GV, Thompson JF. Evolving concepts in melanoma classification and their relevance to multidisciplinary melanoma patient care. *Mol Oncol* 2011; **5**:124–136.
- Davis LE, Shalin SC, Tackett AJ. Current state of melanoma diagnosis and treatment. *Cancer Biol Ther* 2019; **20**:1366–1379.
- Cheng L, Lopez-Beltran A, Massari F, MacLennan GT, Montironi R. Molecular testing for BRAF mutations to inform melanoma treatment decisions: a move toward precision medicine. *Mod Pathol* 2018; **31**:24–38.
- Long GV, Weber JS, Infante JR, Kim KB, Daud A, Gonzalez R, et al. Overall survival and durable responses in patients with BRAF V600-mutant metastatic melanoma receiving dabrafenib combined with trametinib. *J Clin Oncol* 2016; **34**:871–878.
- Long GV, Stroyakovskiy D, Gogas H, Levchenko E, de Braud F, Larkin J, et al. Dabrafenib and trametinib versus dabrafenib and placebo for Val600 BRAF-mutant melanoma: a multicentre, double-blind, phase 3 randomised controlled trial. *Lancet* 2015; **386**:444–451.
- Ugurel S, Röhmel J, Ascierto PA, Flaherty KT, Grob JJ, Hauschild A, et al. Survival of patients with advanced metastatic melanoma: the impact of novel therapies. *Eur J Cancer* 2016; **53**:125–134.
- Cope NJ, Novak B, Liu Z, Cavallo M, Gunderwala AY, Connolly M, Wang Z. Analyses of the oncogenic BRAFD594G variant reveal a kinase-independent function of BRAF in activating MAPK signaling. *J Biol Chem* 2020; **295**:2407–2420.
- Dankner M. Targeted therapy for colorectal cancers with non-V600 BRAF mutations: perspectives for precision oncology. *JCO Precis Oncol* 2018; **2**:1–12.
- Smalley KS, Xiao M, Villanueva J, Nguyen TK, Flaherty KT, Letrero R, et al. CRAF inhibition induces apoptosis in melanoma cells with non-V600E BRAF mutations. *Oncogene* 2009; **28**:85–94.
- Johnson DB, Zhao F, Noel M, Riely GJ, Mitchell EP, Wright JJ, et al. Trametinib activity in patients with solid tumors and lymphomas harboring BRAF non-V600 mutations or fusions: results from NCI-MATCH (EAY131). *Clin Cancer Res* 2020; **26**:1812–1819.
- Xing M, Liu R, Liu X, Murugan AK, Zhu G, Zeiger MA, et al. BRAF V600E and TERT promoter mutations cooperatively identify the most aggressive papillary thyroid cancer with highest recurrence. *J Clin Oncol* 2014; **32**:2718–2726.
- Macerola E, Loggini B, Giannini R, Garavello G, Giordano M, Proietti A, et al. Coexistence of TERT promoter and BRAF mutations in cutaneous melanoma is associated with more clinicopathological features of aggressiveness. *Virchows Arch* 2015; **467**:177–184.
- Liu X, Qu S, Liu R, Sheng C, Shi X, Zhu G, et al. TERT promoter mutations and their association with BRAF V600E mutation and aggressive clinicopathological characteristics of thyroid cancer. *J Clin Endocrinol Metab* 2014; **99**:E1130–E1136.
- Liu R, Zhang T, Zhu G, Xing M. Regulation of mutant TERT by BRAF V600E/ MAP kinase pathway through FOS/GABP in human cancer. *Nat Commun* 2018; **9**:579.
- Tan J, Liu R, Zhu G, Umbricht CB, Xing M. TERT promoter mutation determines apoptotic and therapeutic responses of BRAF-mutant cancers to BRAF and MEK inhibitors: Achilles heel. *Proc Natl Acad Sci U S A* 2020; **117**:15846–15851.
- Liu J, Liu R, Shen X, Zhu G, Li B, Xing M. The genetic duet of BRAF V600E and TERT promoter mutations robustly predicts loss of radiiodine avidity in recurrent papillary thyroid cancer. *J Nucl Med* 2020; **61**:177–182.
- Germann UA, Furey BF, Markland W, Hoover RR, Aronov AM, Roix JJ, et al. Targeting the MAPK signaling pathway in cancer: promising preclinical activity with the novel selective ERK1/2 inhibitor BVD-523 (Ulixertinib). *Mol Cancer Ther* 2017; **16**:2351–2363.
- Sullivan RJ, Infante JR, Janku F, Wong DJL, Sosman JA, Keedy V, et al. First-in-Class ERK1/2 inhibitor ulixertinib (BVD-523) in patients with MAPK mutant advanced solid tumors: results of a phase I dose-escalation and expansion study. *Cancer Discov* 2018; **8**:184–195.