

Abdominal Compartment Syndrome Presenting as Diuretic-Refractory Cardiorenal Syndrome

Brigid Hallinan DO
Lehigh Valley Health Network

Follow this and additional works at: <https://scholarlyworks.lvhn.org/administration-leadership>



Part of the Business Administration, Management, and Operations Commons, Emergency Medicine Commons, Health and Medical Administration Commons, and the Management Sciences and Quantitative Methods Commons

Let us know how access to this document benefits you

Published In/Presented At

Hallinan, B. (2012). Abdominal Compartment Syndrome Presenting as Diuretic-Refractory Cardiorenal Syndrome. *LVHN Scholarly Works*. Retrieved from <https://scholarlyworks.lvhn.org/administration-leadership/52>

This Poster is brought to you for free and open access by LVHN Scholarly Works. It has been accepted for inclusion in LVHN Scholarly Works by an authorized administrator. For more information, please contact LibraryServices@lvhn.org.

Abdominal Compartment Syndrome Presenting as Diuretic-Refractory Cardiorenal Syndrome

Brigid Hallinan, DO

Lehigh Valley Health Network, Allentown, Pennsylvania

Introduction:

Abdominal compartment syndrome (ACS) is an increasingly recognized condition, defined as sustained intra-abdominal pressure ≥ 20 mmHg with resultant organ dysfunction.¹ Most often associated with critically ill patients in the setting of trauma, abdominal surgery, sepsis, pancreatitis, massive fluid resuscitation, or intra-abdominal hemorrhage, ACS can also result from third-spacing of fluid into the abdomen in patients with acute decompensated heart failure (ADHF). Here, I present a case of ACS in the setting of diuretic-refractory cardiorenal syndrome (CRS).

Case Presentation:

History: An 85-year-old Caucasian female presented to the emergency department with progressively worsening shortness of breath, abdominal distention, decreased urine output, and lower extremity edema. She had a history of chronic systolic congestive heart failure (CHF) with a left ventricular ejection fraction (LVEF) of 25% and CKD III with a baseline creatinine of 1.2 mg/dL.

Physical Exam: At the time of presentation, vital signs were T 97.6°F, HR 65 bpm, BP 123/67 mmHg, RR 20 bpm, and SpO₂ 97% on 2 L nasal cannula. She appeared to be comfortable and in no acute distress. Scattered inspiratory wheezes and bibasilar rales were auscultated. Cardiac rhythm was regular, with a 3/6 blowing systolic ejection murmur over the left upper sternal border. Jugular venous distention was noted to the level of the earlobe. The abdomen was mildly distended and firm but nontender and with normoactive bowel sounds. Venous stasis changes and 3+ pitting edema were present in the lower extremities bilaterally.

Diagnostic Studies: Diagnostic studies revealed BUN 54, Cr 1.6 (baseline Cr 1.2), K⁺ 5.6, Na⁺ 136 and HCO₃⁻ 29. Troponin I was mildly elevated, peaking at 0.29 ng/mL. B-type natriuretic peptide (BNP) was elevated at 1644 pg/mL. The EKG showed no acute change as compared with prior studies. A chest X-ray showed pulmonary vascular congestion and new bilateral pleural effusions.

Hospital Course: The patient was admitted for acute systolic CHF exacerbation and IV furosemide therapy was initiated. Despite an escalation of diuretic dosing, the addition of metolazone, and the administration of a constant furosemide infusion, she failed to diurese and remained oliguric throughout her first hospital day.

On the second hospital day, her blood pressure dropped to a nadir of 72/37 and her O₂ requirements increased. Labs revealed an increase in Cr from 1.6 to 2.0 mg/dL and she remained dyspneic and oliguric. A renal ultrasound was obtained, which demonstrated normal kidneys along with mild to moderate ascites. Given her worsening renal function, poor response to diuretics, hypotension, and evidence of ascites on the ultrasound, intra-abdominal pressure was measured using the transvesical technique (Figure 1).² The intra-abdominal pressure was found to be significantly elevated at 35 mmHg, suggesting a diagnosis of abdominal compartment syndrome.

The patient promptly underwent therapeutic paracentesis, which yielded 1.5 L of clear ascitic fluid. Repeat bladder pressure obtained post-paracentesis was still elevated but improved to 22 mmHg. Within four hours of paracentesis, urine output increased to 100 cc/hr with intermittent IV furosemide dosing. The following day, she had significant symptomatic improvement and was successfully transitioned to oral furosemide with continued diuresis.

Within three days of the procedure, her weight decreased by 5 kg, creatinine had returned to her baseline of 1.2 mg/dL and blood pressure and oxygenation were improved. She remained stable and did not require repeat paracentesis or other invasive intervention during her hospitalization. With some medication changes, her heart failure regimen was optimized and she was discharged home in good condition.

Discussion:

Background: Traditionally, cardiorenal syndrome (CRS) type I—acute decompensated congestive heart failure leading to acute kidney injury—was thought to be the result of a low cardiac output state causing poor renal perfusion.³ Recent data, however, highlight the significant contribution of elevated intra-abdominal pressure (IAP) to worsening renal function in acute decompensated heart failure (ADHF). In fact, elevations in IAP may play a larger role in the development of acute kidney injury (AKI) in this setting than decreased cardiac index.³⁻⁴

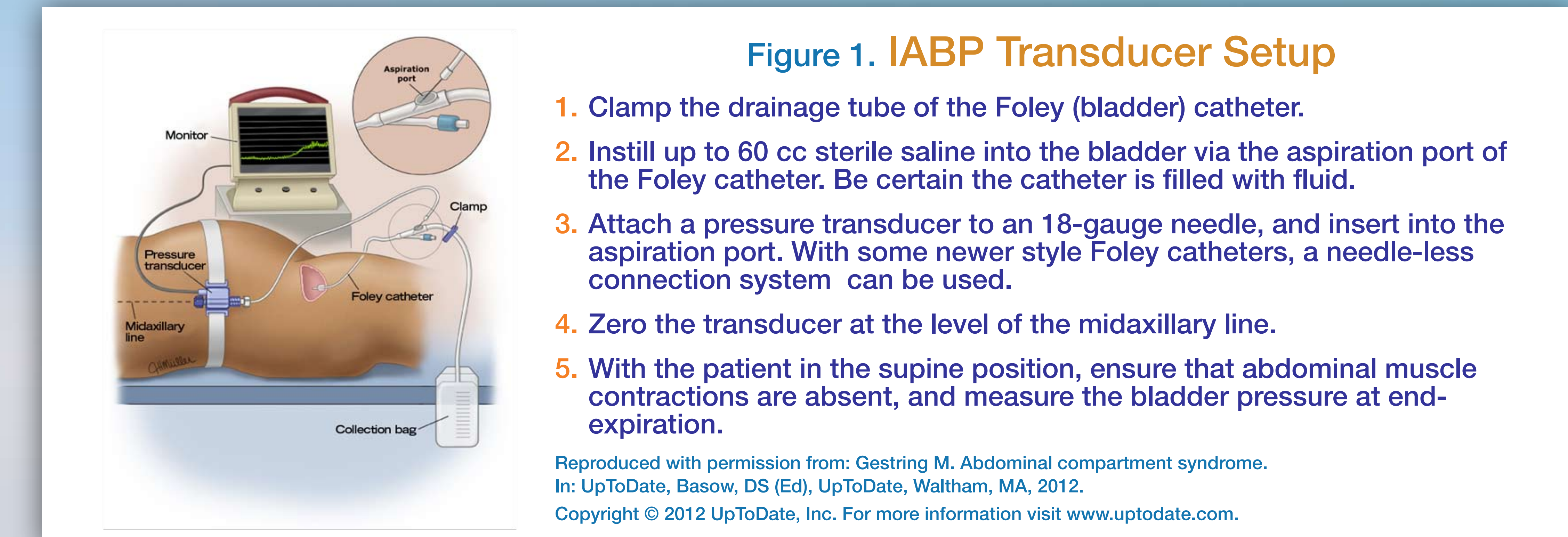
Epidemiology: Elevated IAP (IAP ≥ 8 mmHg) is likely common and under-recognized in patients hospitalized with ADHF. A single-center study reported a 60% prevalence of elevated IAP in a study group of 40 consecutive patients admitted to a heart failure unit with ADHF, with 10% of these total patients meeting the criteria for intra-abdominal hypertension (IAP ≥ 12 mmHg).⁴

Pathophysiology: The mechanisms by which elevated IAP causes worsening renal function include the following: reduction in the glomerular filtration gradient, renal vein and ureter compression, impaired venous return leading to decreased cardiac output, and induction of inflammatory mediators.⁴

Diagnosis: Measurement of IAP by the transvesical technique (Figure 1)² should be performed in CRS patients who are not responding to diuretic therapy. A normal abdominal examination and lack of patient discomfort should not delay IAP measurement in CRS patients. Physical examination findings and patient symptomatology have been found to correlate poorly with measured IAP, possibly owing to the slow increase in IAP in ADHF, as opposed to the rapid IAP increase classically seen in trauma or surgical patients with ACS.⁴

Management: If intra-abdominal hypertension (IAP ≥ 12 mmHg) is detected in a hemodynamically stable patient, conservative management is initially recommended to attempt IAP reduction. Potentially useful techniques include evacuation of intraluminal contents via nasogastric or rectal tube, administration of prokinetic agents, and decreasing or holding enteral feedings. In the case of refractory ileus or colonic pseudo-obstruction, however, colonoscopic decompression may be necessary. Abdominal imaging with CT or ultrasound may reveal ascites amenable to percutaneous drainage. Abdominal wall compliance may be improved with adequate analgesia, removal of constrictive dressings, placing the patient in the reverse Trendelenburg position, or raising the head of the bed to ≥ 20 degrees. In mechanically ventilated patients, neuromuscular blockade can be highly effective in decreasing IAP.⁵ If the patient is agreeable to acute renal replacement therapy, isotonic fluid removal with slow continuous ultrafiltration (SCUF) may be a viable option.⁶

In ADHF patients meeting criteria for ACS (sustained IAP ≥ 20 mmHg with resultant organ dysfunction) more urgent and definitive treatment is warranted. Standard measures for treating intra-abdominal hypertension, as previously described, should still be considered. In particular, the presence of ascites should be sought and fluid promptly removed if present, as decreasing the IAP in this manner can lead to rapid improvement in hemodynamics and renal perfusion.⁷ If paracentesis is not an option or the patient is hemodynamically unstable, surgical evaluation for decompressive laparotomy should be sought without delay.¹



Conclusion:

Elevated intra-abdominal pressure (IAP) is common among patients admitted with acute decompensated heart failure (ADHF) due to third-spacing of fluid into the abdominal compartment. As IAP rises, hemodynamics become further impaired and renal compression ensues, causing poor response to diuretic therapy and clinical deterioration. The diagnosis of intra-abdominal hypertension (IAH) or abdominal compartment syndrome (ACS) should be considered—and IAP measurement obtained—in any patient with oligoanuric AKI in the setting of volume overload, such as in ADHF. If IAH or ACS is diagnosed, the aggressiveness of the therapy warranted depends primarily on the patient's clinical condition rather than the actual measured pressure of the abdominal compartment. In patients with significantly elevated intra-abdominal pressure and resultant acute organ failure, as described in this case, rapid abdominal decompression is indicated to prevent hemodynamic collapse and even death.

References:

1. Cheatham ML, Malbrain ML, Kirkpatrick A, et al. Results from the International Conference of Experts on Intra-Abdominal Hypertension and Abdominal Compartment Syndrome. II. Recommendations. *Intensive Care Med* 2007;951-62.
2. Gestring M. (2012). Abdominal compartment syndrome. UpToDate. Retrieved from <http://www.uptodate.com/contents/abdominal-compartment-syndrome>.
3. Mullens W, Abrahams Z, Francis GS, et al. Importance of venous congestion for worsening of renal function in advanced decompensated heart failure. *J Am Coll Cardiol* 2009;589-96.
4. Mullens W, Abrahams Z, Skouri HN, et al. Elevated intra-abdominal pressure in acute decompensated heart failure. *J Am Coll Cardiol* 2008;300-6.
5. Cheatham ML. Nonoperative management of intraabdominal hypertension and abdominal compartment syndrome. *World J Surg* 2009;1116-22.
6. Ronco C, Haapio M, House AA, et al. Cardiorenal syndrome. *J Am Coll Cardiol* 2008;1527-39.
7. Mullens W, Abrahams Z, Francis GS, et al. Prompt reduction in intra-abdominal pressure following large-volume mechanical fluid removal improves renal insufficiency in refractory decompensated heart failure. *J Card Fail* 2008;508-14.

Contact Information: Brigid K. Hallinan, DO
1240 S. Cedar Crest Blvd.
Suite 410
Allentown, PA 18103
(610) 402-5200
brigid.hallinan@gmail.com