

Rectal Polyp with Atypical Lymphoid Infiltrate; Rectal Lymphoma or Rectal Tonsil

Dalya El Tawil MD
LVHN, dalya.eltawil@lvhn.org

Adam R. Paul DO
Lehigh Valley Health Network, Adam_R.Paul@lvhn.org

Follow this and additional works at: <https://scholarlyworks.lvhn.org/pediatrics>



Part of the [Pediatrics Commons](#)

Let us know how access to this document benefits you

Published In/Presented At

El Tawil, D., Paul, A. & Grau, J. (2014, October, 22). *Rectal Polyp with Atypical Lymphoid Infiltrate; Rectal Lymphoma or Rectal Tonsil*. Poster session presented at the NASPGHAN 2014 Annual Meeting and Postgraduate Course, Atlanta, GA.

This Poster is brought to you for free and open access by LVHN Scholarly Works. It has been accepted for inclusion in LVHN Scholarly Works by an authorized administrator. For more information, please contact LibraryServices@lvhn.org.

Rectal Polyp with Atypical Lymphoid Infiltrate; Rectal Lymphoma or Rectal Tonsil

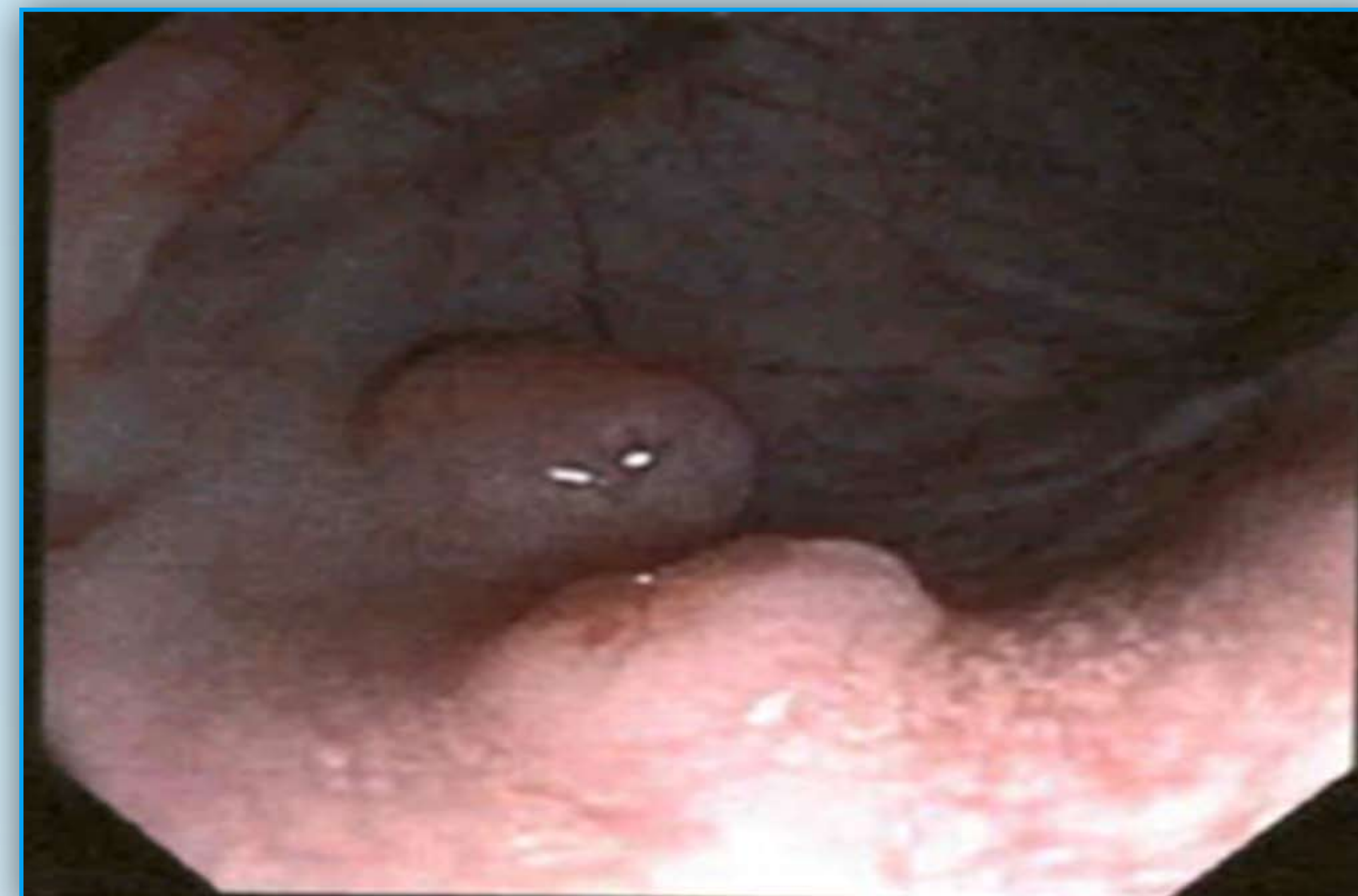Dalya El Tawil, MD, Adam Paul, DO, and Jillian Grau, MD
Lehigh Valley Health Network, Allentown, PA

Introduction

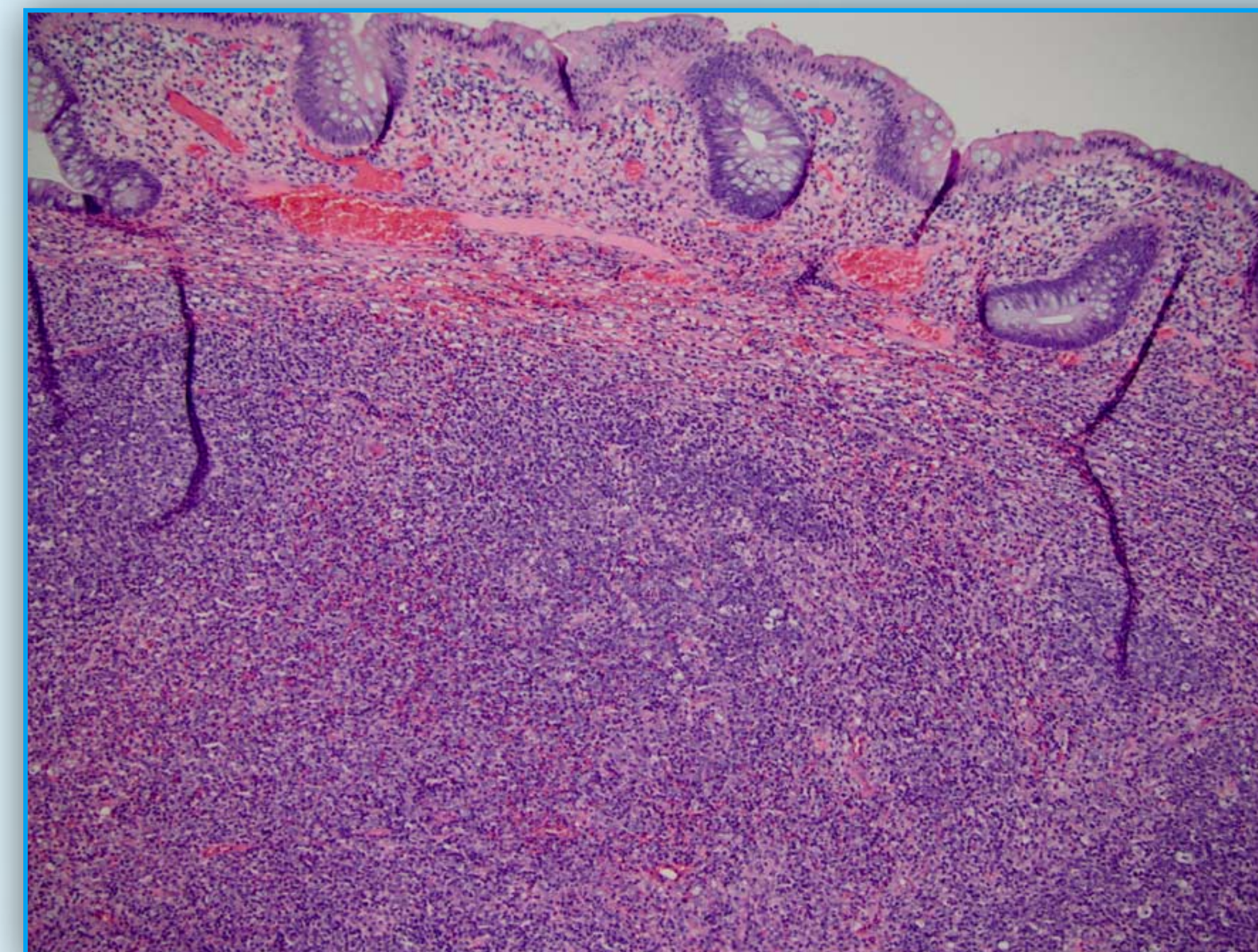
- Rectal polyps are a common cause of rectal bleeding.
- In most instances, rectal polyps are benign hamartomatous juvenile polyps.
- Though the finding is rare, gastrointestinal lymphomas should be considered when polyps contain atypical lymphoid infiltrates.
- Rectal tonsils are benign localized reactive proliferations of lymphoid tissue not commonly reported in children.
- The rectal tonsil appears as a polyp and resembles lymphoma under histological examination.

Case Presentation

- 6 year old previously healthy male presents with 4 weeks of hematochezia.
- The patient underwent EGD & colonoscopy and a 1 cm pedunculated polyp in the distal rectum was excised by snare polypectomy and sent for pathology.
- The polyp was shown to have atypical lymphoid infiltrate involving the mucosa and the submucosa of the rectum.
- The pathology report was initially consistent with rectal lymphoma
- Immunophenotype and the molecular studies then were performed which favored reactive lymphoid hyperplasia consistent with a rectal tonsil.
- The esophageal biopsies showed a slight increase in eosinophils, the remainder of the gastric, duodenal, colonic, and terminal ileal biopsies showed no diagnostic abnormalities.



Polyps seen on endoscopy



Section of excised polyp shows a large asymmetric germinal centers with large transformed interfollicular lymphocytes.

Discussion

- The rectal tonsil, also known as the benign lymphoid polyp, can present with intermittent rectal bleeding or pain.
- On endoscopy it is usually located in the rectum just proximal to the dentate line.
- Its histology mimics a gastrointestinal lymphoma, which is the most common extra nodal location of lymphoma.
- Diagnosis of rectal lymphomas require supportive immunohistochemical staining and genotypic studies.
- The treatment for a rectal tonsil is local excision.
- Since the endoscopic and histologic appearance is similar to rectal lymphoma it is critical to perform further testing on path sections.

Conclusions

- When the histology of a polyp is suggestive of lymphoma, it is important to include rectal tonsil in the differential diagnosis. This can help decrease or avoid undue familial anxiety, additional medical testing and referrals.

References:

- 1 Farris, AB, et al. The rectal tonsil: a reactive lymphoid proliferation that may mimic lymphoma. Am J Surg Pathol. 2008 Jul;32(7):1075-9.
- 2 Kojima M., et al. Localized lymphoid hyperplasia of the rectum resembling polypoid mucosa-associated lymphoid tissue lymphoma: a report of three cases. Pathol Res Pract 2005; 201:757-761.

© 2014 Lehigh Valley Health Network