

Subacute Cutaneous Lupus Erythematosus with Erythema Multiforme-like Lesions: Consideration for Rowell Syndrome

Kelly L. Reed DO

Lehigh Valley Health Network, Kelly_L.Reed@lvhn.org

Steven Oberlender MD, PhD

Lehigh Valley Health Network, Steven.Oberlender@lvhn.org

Stephen M. Purcell DO

Lehigh Valley Health Network, Stephen.Purcell@lvhn.org

Follow this and additional works at: <https://scholarlyworks.lvhn.org/medicine>



Part of the [Dermatology Commons](#), and the [Medical Sciences Commons](#)

Let us know how access to this document benefits you

Published In/Presented At

Reed, K., Oberlender, S., & Purcell, S. (2014, March 14). *Subacute cutaneous Lupus erythematosus with erythema multiforme-like lesions: Consideration for rowell syndrome*. Poster presented at: The Philadelphia Dermatological Society Conference, Philadelphia, PA.

This Poster is brought to you for free and open access by LVHN Scholarly Works. It has been accepted for inclusion in LVHN Scholarly Works by an authorized administrator. For more information, please contact LibraryServices@lvhn.org.

Subacute Cutaneous Lupus Erythematosus with Erythema Multiforme-like Lesions: Consideration for Rowell Syndrome

Kelly L. Reed, DO, Steven A. Oberlender, MD, PhD and Stephen M. Purcell, DO
Lehigh Valley Health Network, Allentown, Pennsylvania

Case Presentation:

Patient: 83 year-old Caucasian male.
History of Present Illness: The patient presented to the emergency department with a ten day history of a mildly pruritic generalized rash which developed after completing a course of high dose oral prednisone for previously diagnosed idiopathic thrombocytopenic purpura (ITP). He denied any other new medications. The patient had a 10 year history of discoid lupus erythematosus (DLE) which was under control with only sun protection. A review of systems was negative for joint pains, oral ulcers, headache, and other systemic findings except for fatigue, which began around the time of the patient's skin findings. He denied any recent treatments for the rash and had no history of a similar problem in the past. There was also no reported history of herpetic lesions.

Medical History/Surgical History: Discoid lupus erythematosus, ITP, celiac disease, GERD, history of prostate cancer status post radiation therapy
Current Medications: Pantoprazole, tamsulosin, zinc oxide ointment

Physical Examination: The patient had multiple erythematous thin papules, some with dusky centers giving a targetoid appearance, coalescing into plaques on the scalp, neck, ears, trunk and extremities. Thin red annular plaques were seen on the palms. There were scattered vesicles on the trunk and extremities that desquamated with light pressure. Purpuric thin papules and plaques were present on the legs. The face was spared and there was no oral or conjunctival involvement. Lesions consistent with discoid lupus were not identified.

Laboratory Data: CBC WNL except platelets 81,000 (150,000-400,000/microliter), ANA 1:2560 (<40 titer) speckled pattern, SSA 155, SSB 167 (normal <20). Anti-dsDNA, RNP, Smith, Scl-70, anti-histone, p-ANCA, and c-ANCA WNL.

Studies: Chest x-ray: Negative
Biopsy: *Health Network Labs* (S13-25193, 7/30/2013) Left lateral arm: Interface and subepidermal vesicular dermatitis with scattered single dyskeratotic keratinocytes. Regions of confluent thickness keratinocytic necrosis, consistent with erythema multiforme. Colloidal iron stain showed increased dermal mucin.

Mayo Medical Labs (IR13-3745, 7/30/2013) Left lateral arm DIF: IgG- strong stippled granular deposition overlying keratinocyte cytoplasm. IgA, IgM and fibrinogen negative

Diagnosis: Subacute Cutaneous Lupus Erythematosus with Erythema Multiforme-like Lesions

Treatment: Plaquenil 400 mg daily and a one month prednisone taper beginning at 20mg resulted in rapid improvement. At six months follow-up he had near complete resolution, maintained on Plaquenil.

Initial Presentation

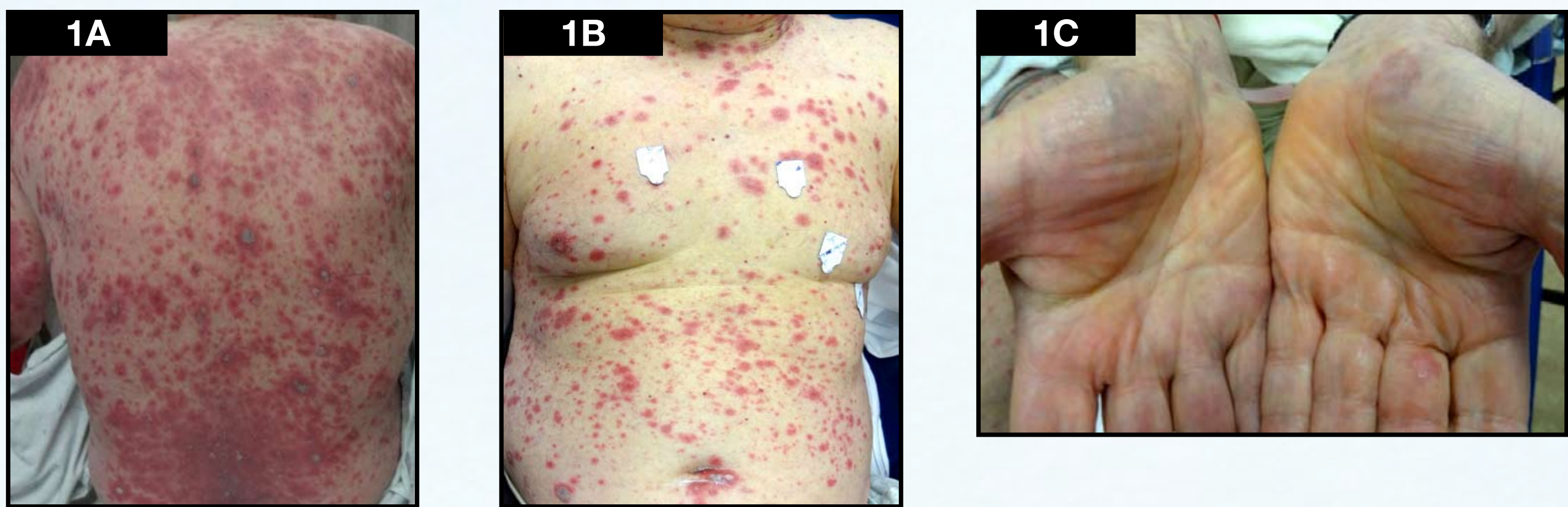

Figure 1 (A-C): (A & B) Multiple erythematous thin scaly papules, some with targetoid appearance, coalescing into plaques noted on the neck, ears, back, chest and arms. (C) Thin, red, annular plaques on the palms.

Two Weeks With Treatment

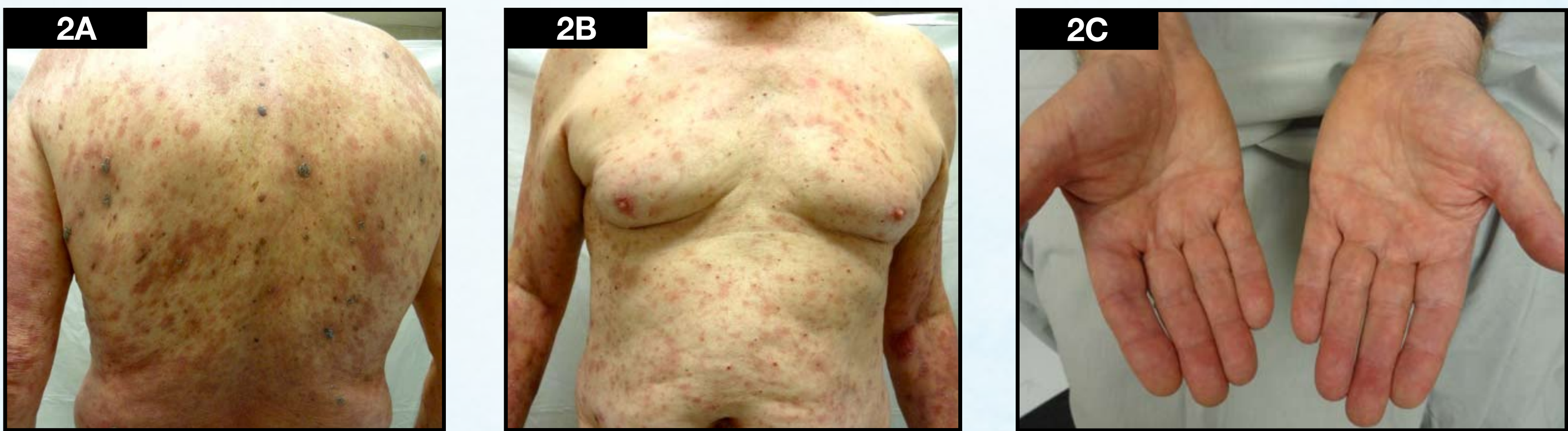

Figure 2 (A-C): Significantly reduced erythema and size of lesions after treatment with prednisone and Plaquenil.

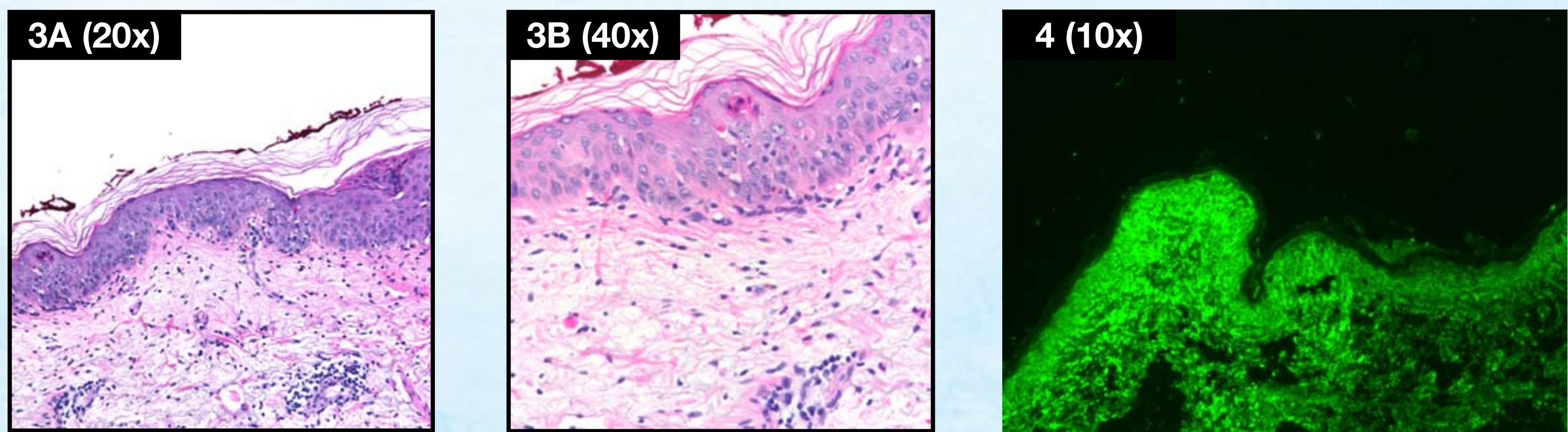


Figure 3 (A-B): H&E punch biopsy of lesional skin on left lateral arm demonstrating normal stratum corneum with an interface and subepidermal vesicular dermatitis. There are scattered necrotic keratinocytes with areas of confluent necrosis, consistent with erythema multiforme. Figure 4: DIF from the left lateral arm with IgG deposition in a stippled, granular pattern over keratinocyte cytoplasm.

Table 1. Zeitouni et al criteria (2000)

Need 3 major and 1 minor	
Major criteria	SLE, DLE or SCLE
	EM-like lesions
	Speckled ANA pattern
Minor criteria	Anti-Ro/SS-A
	Anti-La/SS-B
	Positive rheumatoid factor

Table 2. Torchia et al criteria (2012)

Need 4 major and 1 minor	
Major criteria	CCLC (DLE or chilblain)
	EM-like lesions
	1 pos (speckled ANA, anti-Ro/SS-A, anti-La/SSB)
	Neg DIF on lesional EM-like lesions
Minor criteria	No triggering factors (medications or infection)
	Lack of EM lesions on acral or mucosal surfaces
	One other diagnostic criteria for SLE excluding discoid or malar rash, ANA, photosensitivity or oral ulcers

Discussion:

In 1963, Rowell et al. proposed the coexistence of DLE with EM-like lesions and immunologic abnormalities to be a distinct entity, subsequently termed Rowell Syndrome (RS). The features of RS were described in four patients with history of discoid lupus and included lupus erythematosus, erythema multiforme-like lesions and specific serologic abnormalities (speckled pattern ANA, SS-B, and positive rheumatoid factor). Since the original description of RS, case reports have infrequently appeared in the literature, most commonly occurring in young to middle aged Caucasian women. There has been controversy regarding its existence as a distinct entity, however, as some have suggested it to be a coincidental occurrence of EM and LE or simply a variant of LE. Since its original description, new diagnostic criteria have been proposed and revised in order to better define potential cases of RS.

Criteria proposed in 2000 by Zeitouni et al. consist of three major and three minor criteria, of which, all three major and one minor criteria are required for diagnosis (Table 1). According to these criteria, our patient could appropriately be labeled as having RS. However, more recent criteria from 2012 was proposed by Torchia and colleagues based on an extensive literature review identifying 95 cases of reported RS of lupus with EM lesion morphology. This set of guidelines requires all four of the major criteria and one minor (Table 2).

Our patient presented with a reported history of DLE and clinically exhibited targetoid lesions that were histopathologically consistent with erythema multiforme. Serology showed positivity for speckled pattern ANA, SS-A and SS-B, findings reported in RS but also fairly specific for SCLE. Direct immunofluorescence (DIF) revealed granular IgG deposition over epidermal keratinocytes. This finding is reported in, though not exclusive to SCLE and thought to be due to anti-Ro antibodies. In contrast, EM rarely has positive DIF, though when present is typically IgM or C3 involving the basement membrane zone and superficial blood vessels.

Application of the aforementioned diagnostic criteria for RS reveals this patient met the criteria presented by Zeitouni et al. However, the positive DIF and lack of discoid lupus lesions clinically would result in exclusion from the criteria described by Torchia et al. Furthermore, the patient responded well to Plaquenil and corticosteroids, treatment commonly used for SCLE, though corticosteroids may also be effective in EM. Considering the lack of agreement in current literature, failure to meet the most recent proposed criteria, findings and response to therapy more consistent with SCLE without precipitating factors of EM, this patient best fits the description SCLE with EM-like lesions, as opposed to RS.

The question remains as to whether or not RS exists. There may be a subset of patients for whom RS is an appropriate diagnosis. However, recent literature appears to suggest it is merely an interesting morphological variant of lupus erythematosus and many cases previously reported as RS may have simply been acute or subacute cutaneous lupus with EM-like lesions, much like this case.

References:

- 1 Youchoi R, Cronin PM. Case Report: Systemic Lupus Erythematosus Associated with erythema multiforme-like lesions. *Case Reports in Rheumatology*. 2013; 3 pages. Web 10 Jan 2014.
- 2 Torchia D, Romanelli P, Kerdel FA. Erythema multiforme and Stevens-Johnson syndrome/toxic epidermal necrolysis associated lupus erythematosus. *J Am Acad Dermatol*. 2012 Sept;63:417-423.
- 3 Zeitoni NC, Funaro D, Cloutier RA, Gagné E, Claveau J. Redefining Rowell syndrome. *Br J Dermatol*. 2000 Feb;142(2):343-6.

© 2014 Lehigh Valley Health Network