

New Vein Compression Entities in Patients with Unexplained Leg Swelling.

Alaina Garrie DO

Lehigh Valley Health Network, Alaina.Garrie@lvhn.org

Lauren E. Jones

Julia F. Chen

Robert W. Feldtman

Kenneth R. Kollmeyer

See next page for additional authors

Follow this and additional works at: <https://scholarlyworks.lvhn.org/emergency-medicine>



Part of the [Emergency Medicine Commons](#), [Family Medicine Commons](#), and the [Surgery Commons](#)

Published In/Presented At

Garrie, A., Jones, L. E., Chen, J. F., Feldtman, R. W., Kollmeyer, K. R., Richmond, J. L., & ... Ahn, S. S. (2017). New Vein Compression Entities in Patients with Unexplained Leg Swelling. *Annals Of Vascular Surgery*, doi:10.1016/j.avsg.2017.06.044

This Article is brought to you for free and open access by LVHN Scholarly Works. It has been accepted for inclusion in LVHN Scholarly Works by an authorized administrator. For more information, please contact LibraryServices@lvhn.org.

Authors

Alaina Garrie DO, Lauren E. Jones, Julia F. Chen, Robert W. Feldtman, Kenneth R. Kollmeyer, Jasmine L. Richmond, Craig A. Ferrara, Pablo V. Uceda, Lelesse Mocio, and Samuel S. Ahn

New Vein Compression Entities in Patients with Unexplained Leg Swelling

Alaina Garrie,¹ Lauren E. Jones,² Julia F. Chen,³ Robert W. Feldtman,² Kenneth R. Kollmeyer,² Jasmine L. Richmond,² Craig A. Ferrara,² Pablo V. Uceda,² Lesse Mocio,⁴ and Samuel S. Ahn,² Allentown, Pennsylvania, Dallas, Texas, New Haven, Connecticut, and Chestnut Hill, Massachusetts

Background: This retrospective study identifies often overlooked anatomical sites for non-thrombotic venous outflow obstruction (NTVO) in patients with unexplained lower extremity edema and pain.

Methods: We reviewed the charts of 75 consecutive patients experiencing symptoms of unexplained lower extremity edema with pain that were unexplained by ultrasound, computed tomography angiography (CTA), and magnetic resonance imaging (MRI), who subsequently underwent venography in an outpatient medical office from 2010 to 2014. We categorized venograms based on the presence or absence of NTVO lesions and calculated prevalence of each at specific sites. The patients with NTVO lesions showing >50% stenosis on venography were then treated with angioplasty and/or stenting. After intervention, we documented subjective levels of pain and edema.

Results: Of the 75 venograms reviewed, physicians classified 52 as normal and 23 as showing evidence of compression, including 9 with May-Thurner syndrome and 14 with anatomical compressions at previously underreported sites. These 14 compression sites occurred at the following: iliofemoral vein at the inguinal ligament region ($n = 7$, 50%), external iliac vein at the iliac artery bifurcation ($n = 1$, 7.1%), both inguinal ligament region and iliac artery bifurcation ($n = 4$, 28.6%), and popliteal vein at the popliteal fossa ($n = 2$, 14.3%). Nine of the 14 patients (64.3%) reported total or near total resolution of lower extremity pain and edema at follow-up between 1 and 7 months (mean = 5.3 ± 2 months, median = 6 months) after balloon angioplasty and/or stent. Five with failed primary interventions underwent subsequent stenting and/or angioplasty and reported total or near total resolution of pain and clinical resolution of edema.

Conclusions: This study provides evidence to broaden the disease profile of venous compression syndromes to other sites such as the hypogastric artery, inguinal ligament, and popliteal fossa. The results support previous research that suggests increased incidence of NTVO exists among patients with unexplained lower extremity edema and pain. In an effort to encourage further exploration, we developed a diagnostic algorithm to support a critical and systematic review of patients with lower extremity edema and pain that may go unexplained using traditional diagnostic measures, including ultrasound, CTA, and MRI alone.

Presentation Information: This study was presented in part at the Texas Surgical Society's 196th Fall Semi-Annual Meeting, Austin, Texas, September 15, 2015, and at the Outpatient Endovascular and Interventional Society Third Annual Meeting, Miami Beach, Florida, April 15, 2016.

Funding: This work was supported in part by the California Vascular Research Foundation.

¹Lehigh Valley Hospital, Allentown, PA.

²DFW Vascular Group, Dallas, TX.

³Yale University Medical Center, New Haven, CT.

⁴Boston College, Chestnut Hill, MA.

Correspondence to: Samuel S. Ahn, DFW Vascular Group, 221 West Colorado Blvd., Pavilion II, Suite 625, Dallas, TX 75208, USA; E-mail: ssahn100@gmail.com

Ann Vasc Surg 2017; 45: 173–178

<http://dx.doi.org/10.1016/j.avsg.2017.06.044>

© 2017 Elsevier Inc. All rights reserved.

Manuscript received: November 29, 2016; manuscript accepted: June 5, 2017; published online: 21 June 2017

INTRODUCTION

Unexplained symptoms of lower extremity (LE) edema and pain present a diagnostic challenge to physicians.¹ Vascular surgeons acknowledge the relationship between extrinsic compression syndromes and unexplained pain and swelling in the LEs in the absence of deep vein thrombosis (DVT).^{1–4} In 1957, May-Thurner first described the nonthrombotic venous outflow obstruction (NTVO) of the left common iliac vein by the right common iliac artery.⁵ Shortly thereafter, Cockett et al.⁶ reported on the same phenomenon. Improvements in venous imaging and catheter-based treatments in the 1990s gave physicians the tools for treating and describing additional compression syndromes. We now recognize not only May-Thurner syndrome but also nutcracker syndrome (left renal vein compression), Budd-Chiari syndrome (retrohepatic inferior vena cava compression), and thoracic outlet syndrome (compression of the axillo-subclavian veins and internal jugular veins).⁷

Despite these advancements, many cases of venous outflow obstruction still go widely unreported and unnamed.^{1–3,8,9} For example, only a few case reports describe nonthrombotic obstructive venous lesions of the popliteal vein,^{10–12} which are usually described in conjunction with arterial entrapment with only 10–15% of patients showing concomitant venous involvement. Isolated events of venous popliteal entrapment remain rare.⁴ Woo et al.¹³ offers a case report describing an incidence of iliac vein compression syndrome from anterior perforation of a pedicle screw. In one case report of popliteal venous entrapment in a patient with LE edema, a battery of imaging, including duplex ultrasound, triple-phase bone scan, plain film radiography, magnetic resonance imaging (MRI), and laboratory work did not reveal compression.¹¹ Compression was only revealed when the patient underwent venography. Several existing studies document compression sites at the iliac vein; however, the vast majority reports the left common femoral vein being compressed by the crossing right common iliac artery near the bifurcation of the aorta and inferior vena cava.^{14–16} Raju and Neglen¹ reported the first case of an iliac vein lesion occurring at the hypogastric artery in 2006, but none have been reported since then.

These unique case studies raise the possibility that isolated entrapment may exist at other loci. Our retrospective study adds 14 unique cases to the few existing case reports calling for further investigation of NTVO to broaden the disease profile. In an effort to encourage further exploration,

we developed a diagnostic algorithm to support a critical and systematic review of patients with unexplained LE edema and pain.

MATERIALS AND METHODS

With appropriate Aspire Institutional Review Board approval, we conducted a retrospective review of 75 consecutive patients with subjectively reported LE pain and concurrent edema that were unexplained by diagnostic imaging studies in an outpatient medical office from 2010 to 2014. The presence or absence of edema was reported at clinical follow-up, although reporting on degree of severity was not standardized between physicians. These patients all had a Clinical Etiologic Anatomic Pathophysiologic classification of C3 or above. They had both cross-sectional imaging studies and reflux studies evaluated in the standard fashion,^{17,18} and patients were asked to sit or stand as necessary. All patients had venous duplex ultrasounds that were negative for DVT (both for deep and superficial venous insufficiency). Arterial Doppler studies were also performed, and all were negative for peripheral arterial disease. In addition, these patients had negative computed tomography angiography or MRI scans for pelvic and abdominal masses. All had failed a trial of compression stockings (50% of total study participants wore 15–20 mm Hg, and the others wore stockings at 20–30 mm Hg) for 4 to 6 weeks.

Patients underwent LE venographic imaging. We obtained the venograms by puncture at the greater saphenous vein near the saphenofemoral junction contralateral to the more severely symptomatic leg. We obtained an ascending venogram of bilateral pelvic veins and the inferior vena cava, then advanced the catheter from puncture site to the contralateral tibial veins and obtained ascending venogram of tibial, popliteal, femoral, and then iliac veins, one segment at a time with hand-injected contrast (50% concentration of contrast, 5–10 cc per injection). Provocative maneuvers were not done, as symptoms were constant and not related to any inciting cause. Digital fluoroscopic runs were made for each segment, and images were stacked to obtain peak opacification. Intravascular ultrasound was not available, and thus not performed.

Physicians categorized venograms based on the presence or absence of anatomical compression sites resulting in venous outflow obstruction. Those with compression were further categorized either as having May-Thurner syndrome, or showing compression at additional anatomical sites, including the

iliofemoral vein at the inguinal ligament, external iliac vein at the iliac artery bifurcation, both the inguinal ligament region and iliac artery bifurcation, or the popliteal vein at the popliteal fossa.

All patients with normal venograms continued treatment with compression stockings. Patients in the subgroup with compression at underreported loci underwent the following interventions by 1 of the 5 participating surgeons: percutaneous transluminal angioplasty (PTA) alone, PTA with stenting, or PTA then reintervention with stenting. Indications for intervention were minimum 50% stenosis on venography by diameter measurements, slow flow with delayed emptying, and/or the presence of collateral veins. We documented technical success by completion venography which showed less than 30% residual stenosis with improved flow and/or resolution of collaterals. If angioplasty alone failed to show less than 30% restenosis, improved flow, and/or resolution of collaterals, the patient underwent stenting. Use of LifeStar[®] (Bard Peripheral Vascular, Tempe, Arizona) nitinol self-expanding stents allowed for placement across points of flexion like the inguinal ligament and popliteal fossa.

Postoperatively, all patients were administered aspirin and Plavix routinely for a minimum of 6 months unless patients developed intolerance to either medication. Follow-up with physical examination and duplex ultrasound were scheduled immediately postop within 1 month, every 3 months for the first year, and every 6 months thereafter. Reviewing physicians evaluated patients' postintervention subjective pain levels as well as the presence or absence of edema at follow-up.

RESULTS

Demographics

Of the 75 patients, 36 were female (48%). Average age was 59.46 ± 15.47 years. Common comorbidities included hypertension ($n = 46$, 61.33%), diabetes mellitus ($n = 23$, 30.67%), and coronary artery disease ($n = 14$, 18.67%).

Venography

Of the 75 patients' venograms reviewed, 52 (69.3%) had negative findings, and 23 (30.7%) were positive for compression. In the group that showed compression, 9 (39.1%) had May-Thurner Syndrome, and 14 (60.9%) had compression at previously underreported sites. This subset of 10 females (71.43%) and 4 males (28.57%) included 7 patients (50%) with

iliofemoral vein compression at the inguinal ligament, 1 (7.1%) with external iliac vein compression at the iliac artery bifurcation, 4 (28.6%) at both the inguinal ligament and iliac artery bifurcation, and 2 (14.3%) with compression of the popliteal vein at the popliteal fossa (Fig. 1). Of these 14 patients, 10 were classified with a Clinical Etiologic Anatomic Pathophysiologic score of C3 (71.4%), 2 were C4 (14.3%), and 2 were C6 (14.3%). There were monophasic Doppler waveforms in 50% of these patients upon initial ultrasound, suggesting proximal obstruction. Ten had unilateral symptoms (71.4%; 6 right and 4 left) and 4 had bilateral symptoms (28.6%).

Surgical Intervention

Five patients received PTA alone, 4 were treated with PTA and stent in the same initial procedure, and 5 were treated with PTA and required subsequent reintervention. Altogether, 50% of the 14 patients underwent stenting. All interventions were performed without mortality or morbidity or thrombotic event.

Postintervention Clinical Outcomes

Symptoms of swelling, pain, and ulceration showed immediate improvement in all 14 patients at their 1 to 2 week postintervention appointments. Nine (64%) remained asymptomatic or reported resolution of pain and minimal swelling at follow-up between 1 month and 7 months. The other 5 reported recurrence of edema, discoloration, and pain at clinical follow-up, and underwent secondary intervention by PTA and/or stenting. In 2 of the 5 patients with persisting symptoms, secondary treatment with PTA alone was sufficient to resolve their edema and pain. The other 3 patients had subsequent stenting, and subjectively reported total or near total resolution of pain, and demonstrated full clinical improvement of edema following secondary intervention. No patient required open decompression surgery. Average follow-up period was 5.3 ± 2 months (median = 6 months).

DISCUSSION

The poor general understanding of the incidence and anatomical variations leading to venous compression syndromes stems, in part, from the limitations of imaging techniques available for diagnosis of venous disease.^{1,2,16} The lack of optimal diagnostic imaging strategies may be an influencing factor that can cause providers to overlook initial presenting symptoms of compressions at the

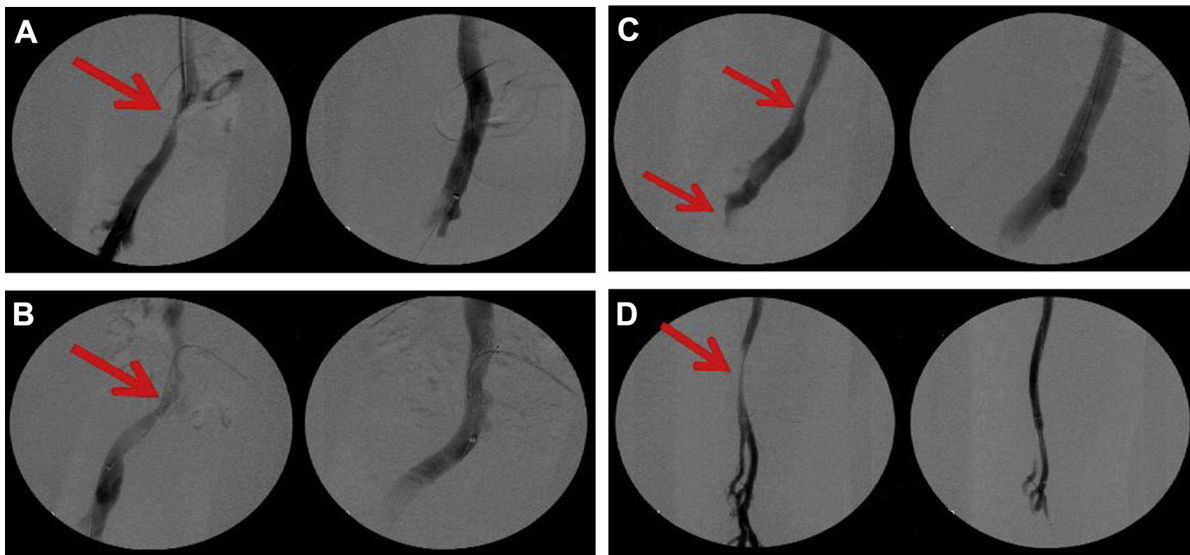


Fig. 1. Examples of diagnostic and postintervention venography of inguinal ligament compression syndrome, iliac bifurcation compression syndrome, and popliteal fossa compression syndrome: **(A)** inguinal ligament compression before (*left*) and after right external iliac and common femoral vein stent placement (*right*). Iliofemoral stents patent at 3 weeks; remained asymptomatic at 5 months. **(B)** Compression at the right external iliac artery bifurcation before (*left*) and after stent placement at the right common/external iliac vein with right common femoral venoplasty (*right*). Pain and edema resolved within 1 week postop. **(C)** Compression at the iliac

bifurcation and inguinal ligament before (*left*) and after stent placement in the external iliac vein and common femoral veins, with right common iliac venoplasty (*right*). Symptoms of pain and edema improved at 1 week follow-up, with no recurrence observed at 6 months. **(D)** Left popliteal vein compression at the popliteal fossa before (*left*) and after left popliteal vein stenting (*right*). Initially presented with bilateral pain, nonhealing ulcers, and swelling. Pain and edema decreased within 1 week postop; ulcers healed and pain resolved within 2 months. *Arrows* indicate the location of venous compression.

iliofemoral venous outflow at the inguinal ligament, external iliac vein at the iliac artery bifurcation, and popliteal vein at the popliteal fossa. This can result in patients living with persistent LE pain and edema without disease-modifying treatment.^{8,19,20}

Unpublished data from our vascular laboratory suggests that decreased spontaneous and phasic flow at the common femoral vein, observed upon initial ultrasound, may correlate with iliac vein stenosis and/or occlusion. With higher resolution equipment available today, reflux with inspiration can be detected hemodynamically. Although the efficacy of this method for diagnosis has not been established, venography has consistently verified the existence of a proximal occlusion in the presence of these signs in cases from 2015 to 2016.

Intravascular ultrasound (IVUS) currently defines the gold standard for detecting iliac vein obstruction,^{16,21} but it did not become accessible for use in the office setting until January 2016. Because of this, IVUS was not available for use in these patients. In some instances, IVUS can be more effective in revealing tight venous lesions that would otherwise be missed in a venogram.^{1,2}

Frontal venogram projections often miss obstructive lesions.¹ Comparing venography to IVUS in limbs with venous obstruction, Neglen and Raju²¹ found venography less accurate than IVUS in detecting obstructions greater than 70%. In the study, Neglen and Raju²¹ support the superiority of IVUS over single-plan venography for morphologic diagnosis of iliac vein outflow obstruction. This may explain why we found NTVO in only 30% of the 75 patients who underwent venography without IVUS. In light of the increased sensitivity of IVUS, we would recommend its use along with venography for future studies examining obstructive lesions in patients with unexplained extremity edema and pain, as outlined in our proposed model for treatment and diagnosis of nonthrombotic obstructive lesions (Fig. 2).

Perhaps, with the increased use of IVUS, there will be an expansion in our understanding of the populations affected by NTVO. The venographic evidence from this study supports the view that obstructive lesions occur predominately in women.¹ The study by Raju and Neglen¹ using IVUS to evaluate NTVO proposes that, with increased use of the technology, practitioners will see an increased prevalence in

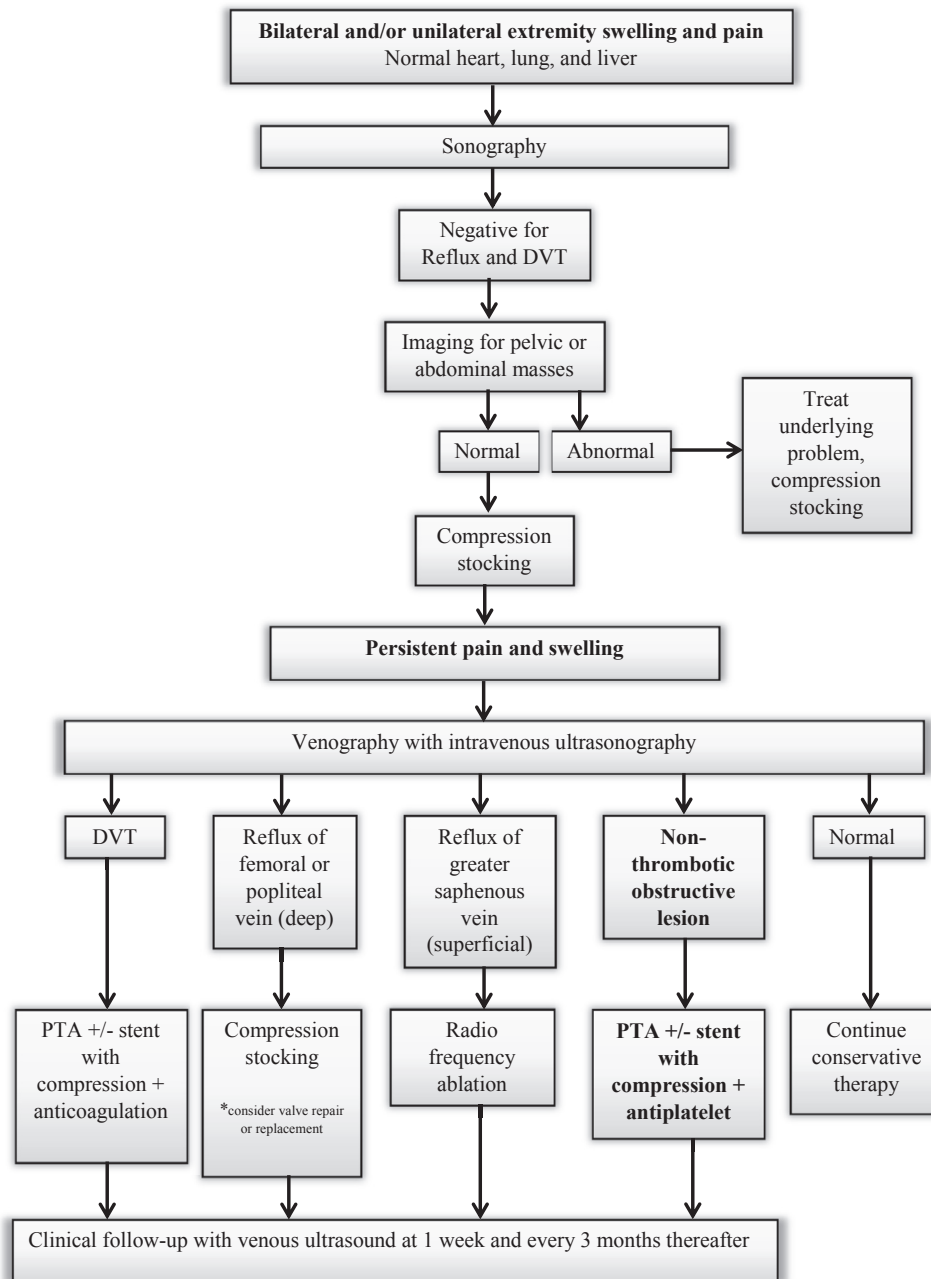


Fig. 2. Algorithm for diagnosis and treatment of non-thrombotic obstructive lesions. Model strategy for treatment and diagnosis of nonthrombotic obstructive

lesions with emphasis on the use of venography with IVUS to diagnose unexplained bilateral or unilateral edema and pain in the extremities.

NTVO among more diverse populations beyond predominantly younger women. A 90-year-old patient included in the study Raju and Neglen calls us to consider that factors beyond cardiac causes can lead to LE edema in elderly patients.¹ Such discrepancies should encourage practitioners to conduct future research using both venography and IVUS to improve diagnostic and treatment strategies for nonthrombotic obstructive lesions. Although many

studies support the use of angioplasty and stenting for the treatment of NTVOs of the iliac vein, few studies elucidate the benefits of similar treatments at less common sites such as reported in our study.^{22–24} Future prospective studies focused on outcomes of stenting and angioplasty of NTVOs may provide further clarity.

In contrast to some previous reports, this study did not report on the degree of pain using the visual

analog scale, which provides more objective evidence than directly asking a patient about pain levels.³ Our study limitations include short follow-up, observer bias, and retrospective design.

CONCLUSION

Venous compression syndromes at the inguinal ligament, iliac bifurcation, and popliteal fossa define significant pathological entities that warrant further thoughtful and comprehensive plans for diagnosis and treatment. The results of our retrospective review support previous reports that suggest detection and treatment of obstruction depends upon critical investigation of the clinical signs and symptoms of pain. We support forming a more strategic approach to diagnostics and treatment of NTVO which includes venogram with IVUS. With continued research and use of the proposed diagnostic algorithm, we expect that even more cases of often overlooked compression syndromes will be diagnosed and treated to alleviate symptoms of LE pain and edema.

The authors thank Amanda Combs, RVT, RDMS, Director of the Vascular Lab at DFW Vascular Group for lending her support and expertise to this project.

REFERENCES

1. Raju S, Neglen P. High prevalence of nonthrombotic iliac vein lesions in chronic venous disease: A permissive role in pathogenicity. *J Vasc Surg* 2006;44:136–44.
2. Birn J, Vedantham S. May-Thurner syndrome and other obstructive iliac vein lesions: Meaning, myth, and mystery. *Vasc Med* 2015;20:74–83.
3. Neglen P, Thrasher T, Raju S. Venous outflow obstruction: An Underestimated contributor to chronic venous disease. *J Vasc Surg* 2003;38:879–85.
4. White JM, Comerota AJ. Venous compression syndromes. *Vasc Endovasc Surg* 2017;51:155–68.
5. Kibbe MR, Ujiki M, Goodwin L, et al. Iliac vein compression in an asymptomatic patient population. *J Vasc Surg* 2004;39:937–43.
6. Cockett FB, Thomas ML, Negus D. Iliac vein compression-its relation to iliofemoral thrombosis and post-thrombotic syndrome. *Br Med J* 1967;2:14–9.
7. Ahn SS, Miller TJ, Chen SW, et al. Internal jugular vein stenosis is common in patients presenting with neurogenic thoracic outlet syndrome. *Ann Vasc Surg* 2014;28:946–50.
8. Butros SR, Liu R, Oliveira GR, et al. Venous compression syndromes: clinical features, imaging findings and management. *Br J Radiol* 2013;86:20130284.
9. Dijkstra ML, Khin NY, Thomas SD, et al. Popliteal vein compression syndrome pathophysiology and correlation with popliteal compartment pressures. *J Vasc Surg Venous Lymphat Disord* 2013;1:181–6.
10. Misselbeck T, Dangleben D, Celani V. Isolated popliteal vein entrapment by the popliteus muscle: a case report. *Vasc Med* 2008;13:37–9.
11. Dean SM. Images in vascular medicine. Popliteal venous entrapment syndrome. *Vasc Med* 2006;11:278–9.
12. Angeli AA, Angeli DA, Aggeli CA, et al. Chronic lower leg swelling caused by isolated popliteal venous entrapment. *J Vasc Surg* 2011;54:851–3.
13. Woo EJ, Ogilvie RA, Van Schaumburger K, et al. Iliac vein compression syndrome from anterior perforation of a pedicle screw. *J Surg Case Rep* 2016;2:1–3.
14. Stuck AK, Kunz S, Baumgartner I, et al. Patency and clinical outcomes of a dedicated, self-expanding, hybrid oblique stent used in the treatment of common iliac vein compression. *J Endovasc Ther* 2017. 1526602816676803.
15. Liu Z, Gao N, Shen L, et al. Endovascular treatment for symptomatic iliac vein compression syndrome: a prospective consecutive series of 48 patients. *Ann Vasc Surg* 2014;28:695–704.
16. Raju S. Best management options for chronic iliac vein stenosis and occlusion. *J Vasc Surg* 2013;57:1163–9.
17. R. Daigle. Venous Colorflow Duplex Imaging of the Lower Extremities. In Program Supplement US: the Basics in Vascular Ultrasound July 31 and August 19, 1997;10–23. TIP-TV 1997, General Electric Company.
18. Priest DL, Zwiebel WJ. Chronic Venous Insufficiency, Varicose Veins, and Saphenous Vein Mapping. In: Zwiebel WJ ed. Introduction to Vascular Ultrasonography. 3rd ed. 1992. pp 323–31.
19. Neglen P. Chronic venous obstruction: diagnostic considerations and therapeutic role of percutaneous iliac stenting. *Vascular* 2007;15:273–80.
20. Walker C. Iliac venous compression syndromes. *Vascular Disease Management*. Available at: <http://www.vascular-disease-management.com/content/iliac-venous-compression-syndromes/>; 2015. Accessed September 20, 2016.
21. Neglen P, Raju S. Intravascular ultrasound scan evaluation of the obstructed vein. *J Vasc Surg* 2002;35:694–700.
22. Neglén P, Tackett TP, Raju S. Venous stenting across the inguinal ligament. *J Vasc Interv Radiol* 2009;20:286.
23. Bozkaya H, Cinar C, Ertugay S, et al. Endovascular treatment of iliac vein compression (May-Thurner) syndrome: angioplasty and stenting with or without manual aspiration thrombectomy and catheter-directed thrombolysis. *Ann Vasc Dis* 2015;8:21–8.
24. Ahmed O, Ng J, Patel M, et al. Endovascular stent placement for May-Thurner syndrome in the absence of acute deep vein thrombosis. *J Vasc and Interv Radiol* 2016;27:167–73.