

Chronic Knee Pain in a Female Field Hockey Player

Charlene I. Jones MD

Nicholas Slenker MD

Follow this and additional works at: <https://scholarlyworks.lvhn.org/family-medicine>



Part of the [Sports Medicine Commons](#)

This Poster is brought to you for free and open access by LVHN Scholarly Works. It has been accepted for inclusion in LVHN Scholarly Works by an authorized administrator. For more information, please contact LibraryServices@lvhn.org.

Chronic Knee Pain in a Female Field Hockey Player

Charlene Jones, MD and Nicholas Slenker, MD¹

Lehigh Valley Health Network, Allentown, PA; ¹Coordinated Health, Allentown, PA

PATIENT PRESENTATION

18 year old female field hockey player presents to sports medicine clinic with left anterior knee pain.

HISTORY

18 year old female field hockey player with past medical history of chronic left anterior knee pain presents to sports medicine clinic with recurrence of her knee pain. She notes patellar instability, pain when going downstairs, and pain with lunging when her knee is bent with weight bearing. She denies pain when running but notices it takes her longer to get warmed up; she can feel herself limping and putting more weight on her right leg. Her symptoms have previously been treated with physical therapy.

She has a history of proximal tibia fracture and ORIF in 2014. She also had a prior MRI of the left knee in May 2018 which showed chondromalacia.

PHYSICAL EXAM

Examination of her left knee revealed increased patellar glide with a 3 quadrant glide, negative patellar apprehension, and no significant pain with patellar grind. There was tenderness to palpation at the superior lateral fat pad. She had full painful range of motion and negative Lachman and also had tight hamstrings and iliotibial band.

DIFFERENTIAL DIAGNOSIS

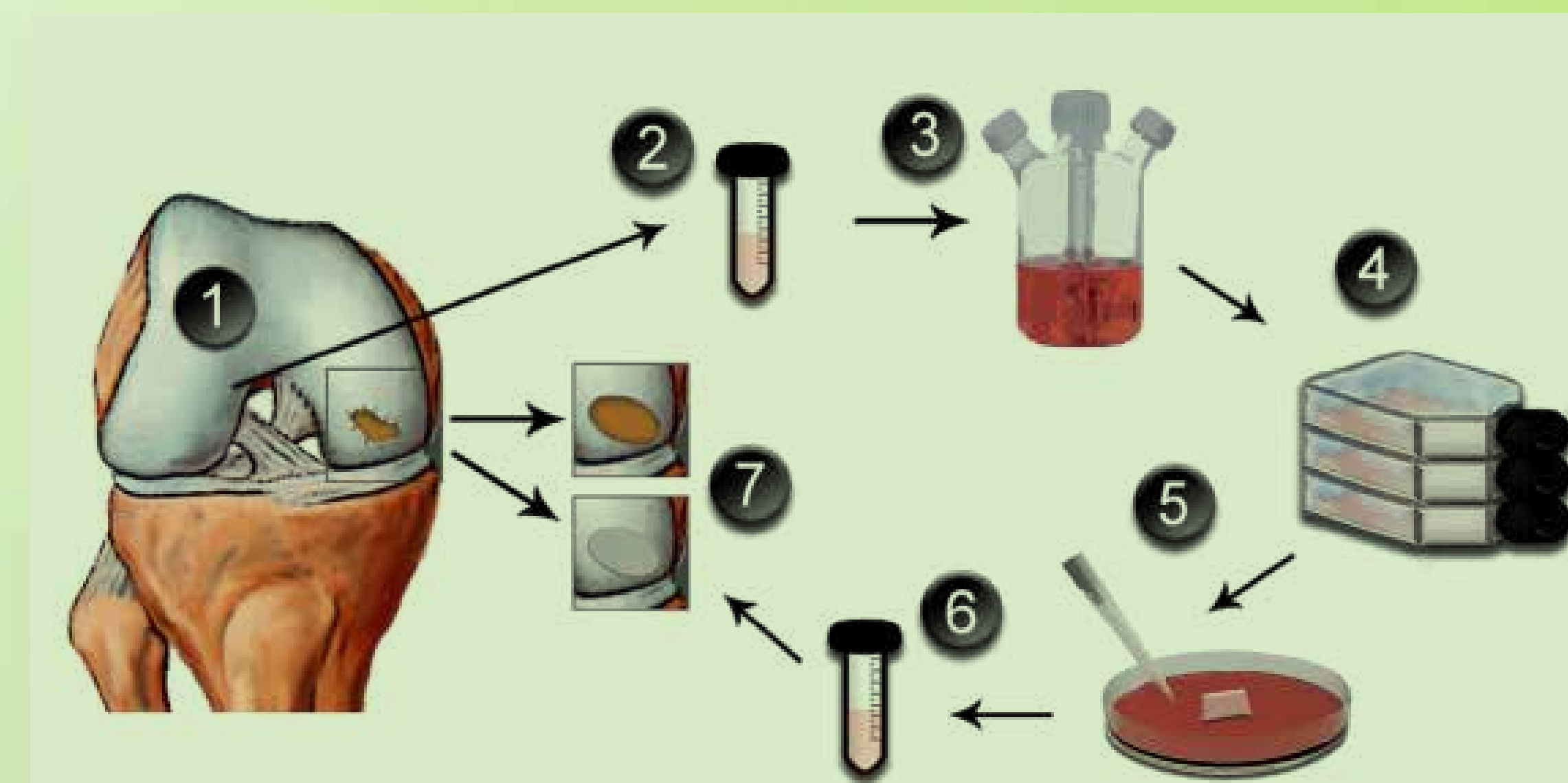
Patellofemoral Pain Syndrome	Osteochondral Defect
Hoffa's Disease	Iliotibial Band Syndrome
	Patellar Instability/Subluxation

FINAL DIAGNOSIS

Patellofemoral articulating osteochondral defect with loose body of the left knee

TREATMENT

Patient was referred to an orthopedic surgeon specializing in cartilage restoration techniques. She was managed surgically with arthroscopic chondroplasty of patella and trochlea followed by matrix-induced autologous chondrocyte implantation (MACI procedure) of the patella and trochlea combined with patellar realignment and open lateral lengthening in staged surgical procedures over a period of two months.



THE MACI PROCEDURE: (1) Initial arthroscopy with evaluation of the injured cartilage and harvest of a full-thickness cartilage biopsy; (2) the biopsy is sent in a sterile and cooled container to the cell culture laboratory; (3) the cartilage is enzymatically digested; (4) expansion of the chondrocytes in monolayer culture for about four weeks; (5) the cells are seeded onto the scaffold a few days before implantation; (6) the engineered implant is sent back to the surgeon in a sterile container; (7) definitive surgery with debridement of the injured cartilage followed by implantation of the MACI-implant, which is trimmed to fit the defect size and glued with a thin layer of fibrin glue.

OUTCOME

Patient tolerated the procedures well and successfully began the post-operative rehabilitation protocol on schedule after a short period of immobilization. At 10 weeks post-op, she continued to increase her range of motion as well as her strength training and weight bearing. At 12 weeks post-op, she was at full weight bearing, progressing with activities of daily living, and increasing her strength training. Running is expected to be initiated at 6 months post-op. Full recovery is expected at approximately 15–18 months post operatively at which time return to play protocol can be initiated.

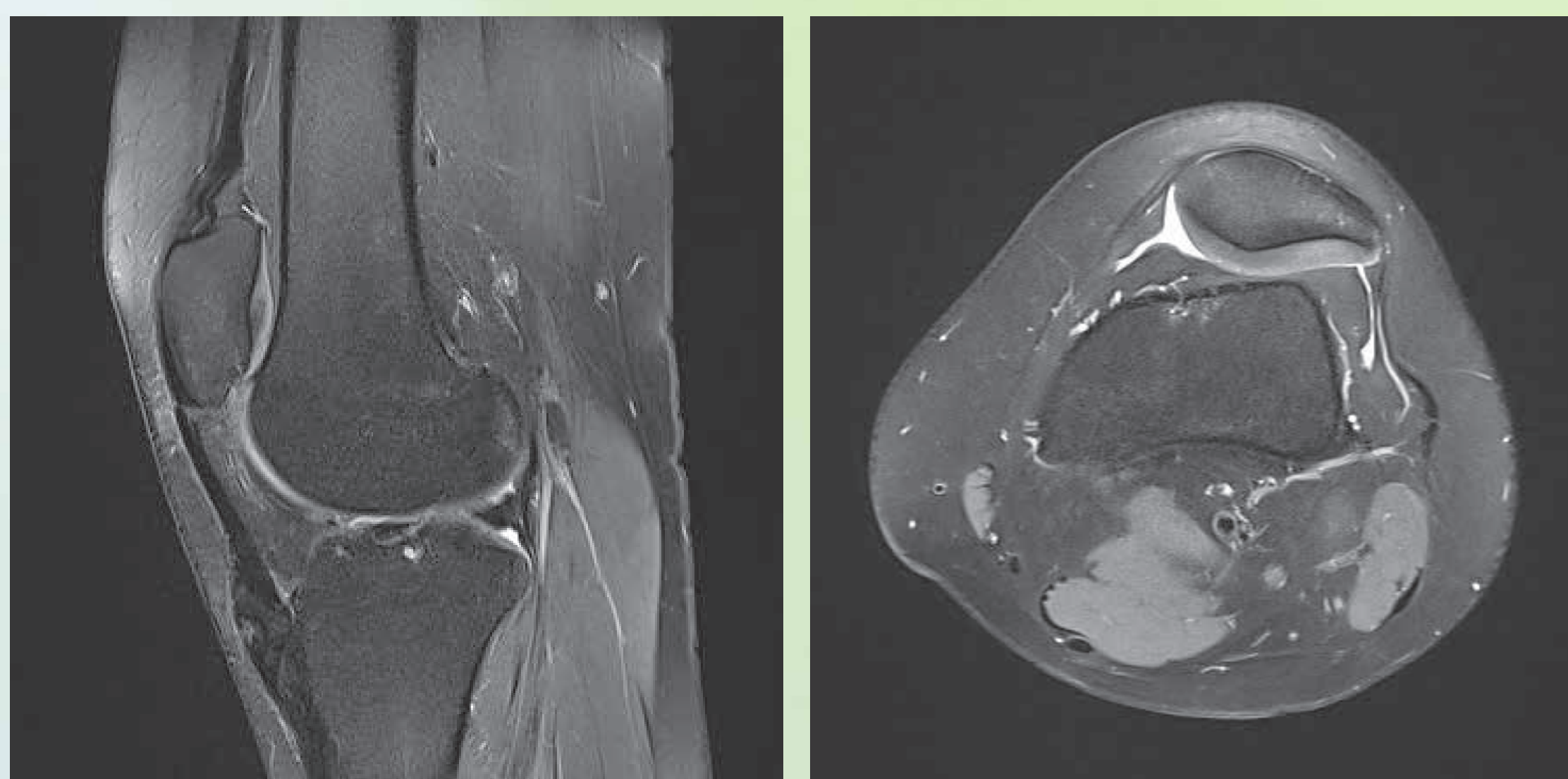
DISCUSSION

Full thickness patellofemoral articulating osteochondral defects (kissing lesions) have been demonstrated in young active patients, but varying treatment modalities remain controversial.¹ The prevalence of chondral lesions found during knee arthroscopic surgery in this patient population has been shown to be between 60–66%, with a prevalence of kissing lesions estimated to be around 6%.¹ Autologous chondrocyte implantation (ACI) is an established treatment for isolated cartilage lesions, but less is known about its efficacy in treating the much rarer kissing lesions.¹ Prior studies have shown unpredictable results of ACI within the patellofemoral compartment, but recent case reports demonstrate good outcomes with this surgical approach for kissing cartilage lesions. The matrix-induced autologous chondrocyte implantation (MACI) technique is a safe two-step procedure that uses cell culture harvesting in order to reduce operative time and the need for open surgery.² Although results in the short term are promising, long term outcome data are lacking. Further research is needed to determine the best treatment and outcomes for patellofemoral articulating osteochondral defects (kissing lesions).

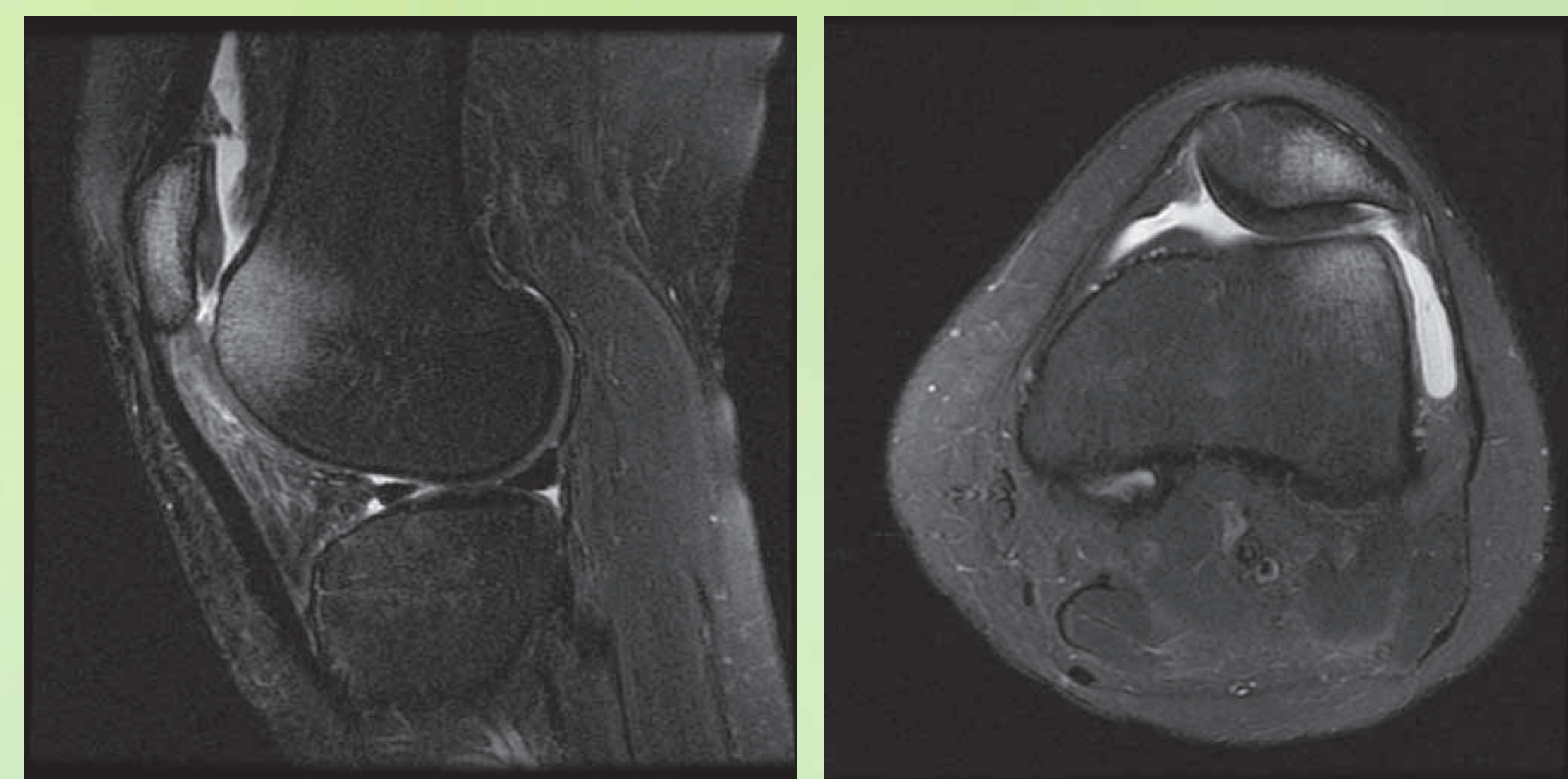
REFERENCES

1. Ridley TJ, Rud CT, Macalena JA. Patellofemoral Articulating Osteochondral (Kissing) Lesion Treated with Autologous Chondrocyte Implantation: A Case Report. *Journal of Orthopaedic Case Reports*. 2017 May-Jun;7(3):41-44.
2. Jacobi et al. MACI - a new era? *Sports Medicine, Arthroscopy, Rehabilitation, Therapy & Technology*. 2011 3:10.

IMAGING



MRI May 2018: Chondromalacia and inflammation around the superior lateral fat pad of left knee.



MRI Sept. 2018: New full thickness osteochondral defect in lateral facet of the patella and trochlea with small visualized loose body.