

Lymphedema in a Hypertrophic Scar: Treatment with Fractional CO2 Laser

Sigrid A. Blome-Eberwein MD
Lehigh Valley Health Network, sigri.blome-eberwein@lvhn.org

Follow this and additional works at: <https://scholarlyworks.lvhn.org/surgery>



Part of the [Other Medical Specialties Commons](#), and the [Surgery Commons](#)

Let us know how access to this document benefits you

Published In/Presented At

Blome-Eberwein, S. (2015, April 21). *Lymphedema in a Hypertrophic Scar: Treatment with Fractional CO2 Laser*. Poster presented at: The 47th Annual Meeting of the American Burn Association, Chicago, IL.

This Poster is brought to you for free and open access by LVHN Scholarly Works. It has been accepted for inclusion in LVHN Scholarly Works by an authorized administrator. For more information, please contact LibraryServices@lvhn.org.

Lymphedema in a Hypertrophic Scar: Treatment with Fractional CO₂ Laser

Sigrid Blome-Eberwein, MD

Associate Director, Regional Burn Center, Lehigh Valley Health Network, Allentown, Pennsylvania

The Case:

The patient is a 34 year old burn survivor of 23 years (48% TBSA 1992 at age 11 from flame) with severe hypertrophic scarring on both lower extremities who developed severe lymphedema in the right ankle with chronic injuries and open wounds over the past 10 years. He has had several surgical intervention attempts with contracture releases and grafting in the past. He continued with frequent episodes of cellulitis due to micro-injuries on base of the significant lymphedema with fibrosis. (Figures 1 and 2)

Before

Figure 1.

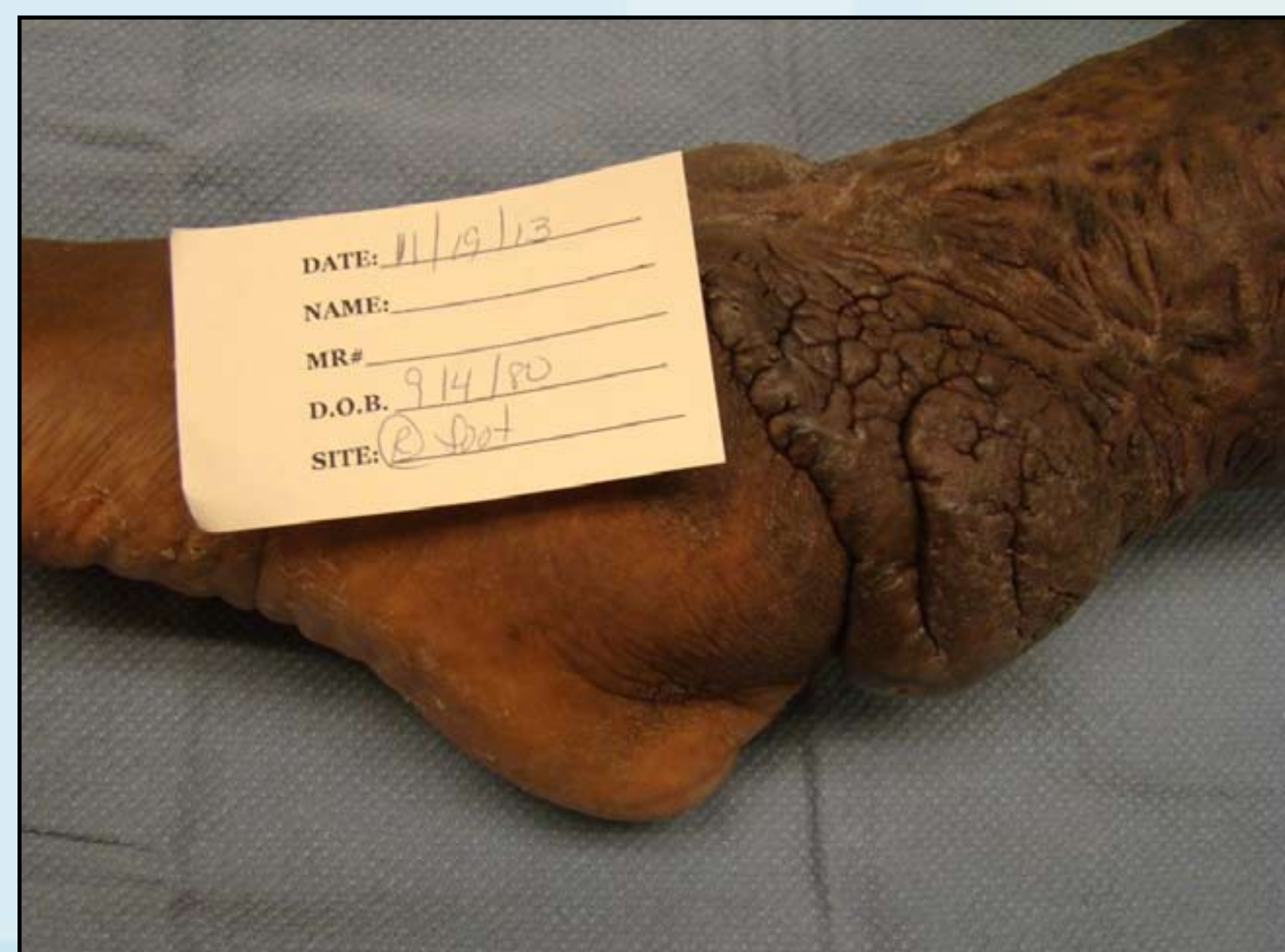
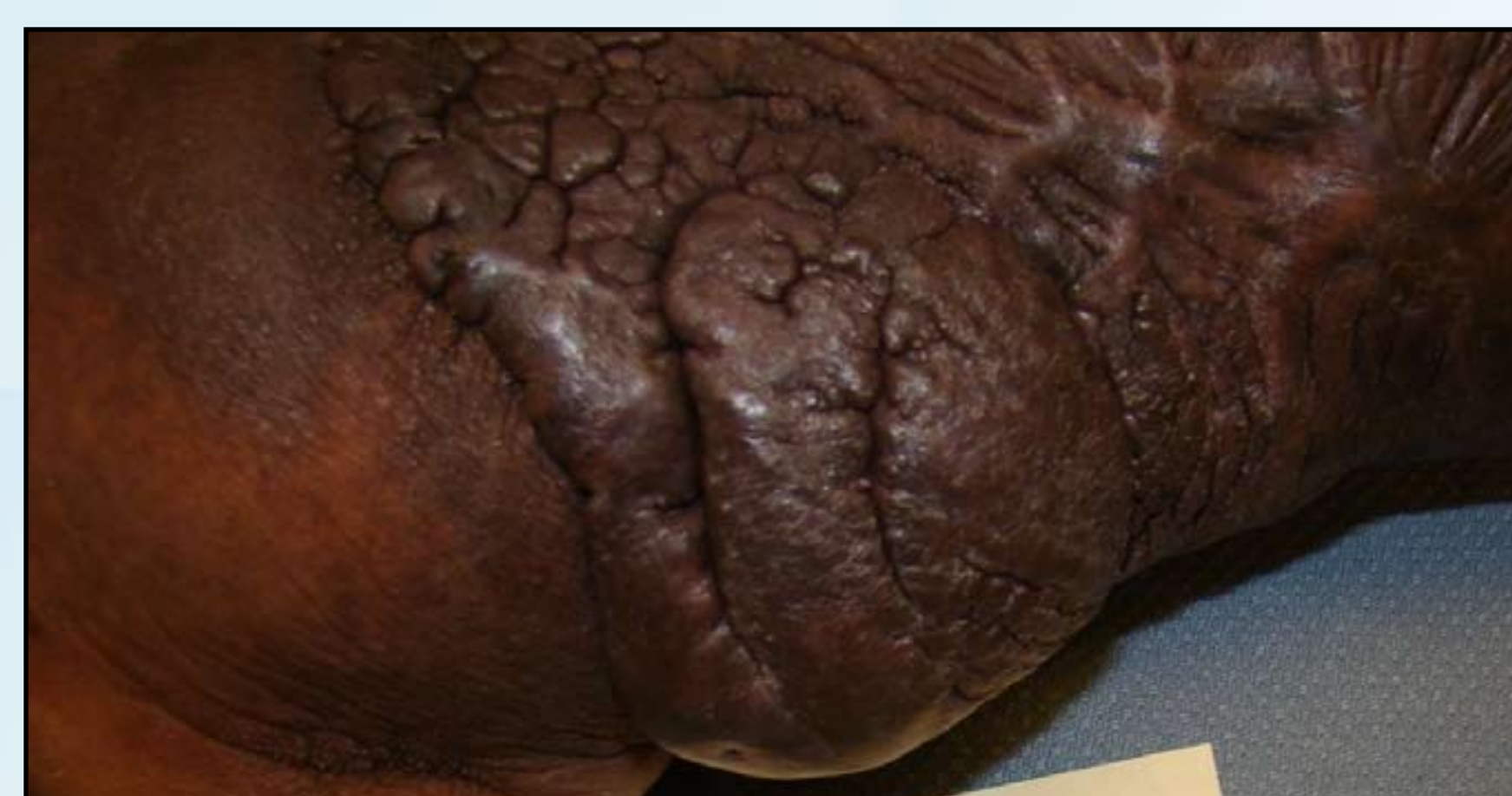

Figure 2.



The Treatment:

- Fractional CO₂ laser treatment was initiated in order to soften the scar and thereby decrease the injury propensity.
- Treatment was applied with a fractional CO₂ laser (eCO₂™, Lutronic®) at 3-4mm depth, 9% density, 6-8 weeks between each treatment.

Immediately After Treatment

Figure 3.

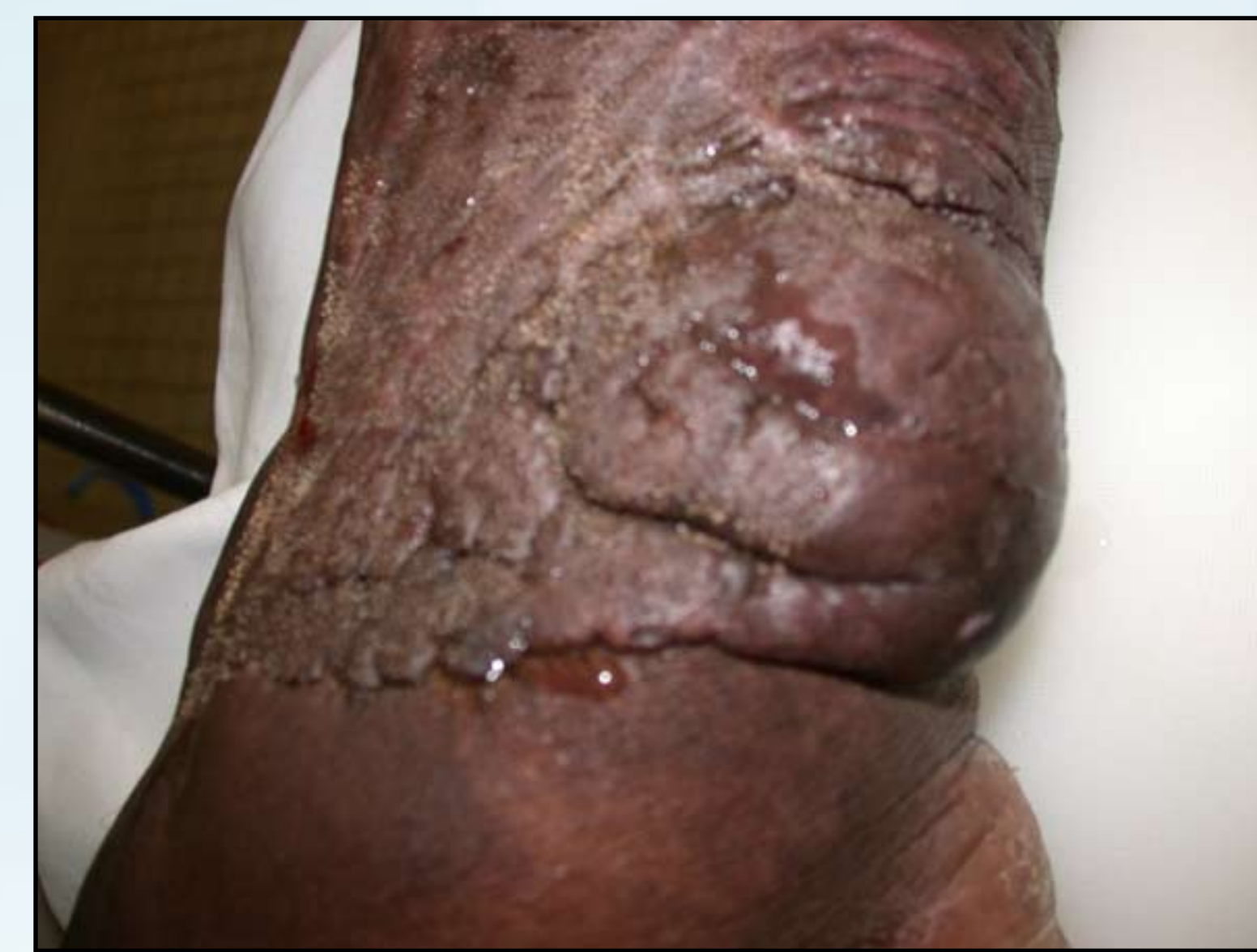

Figure 4a.

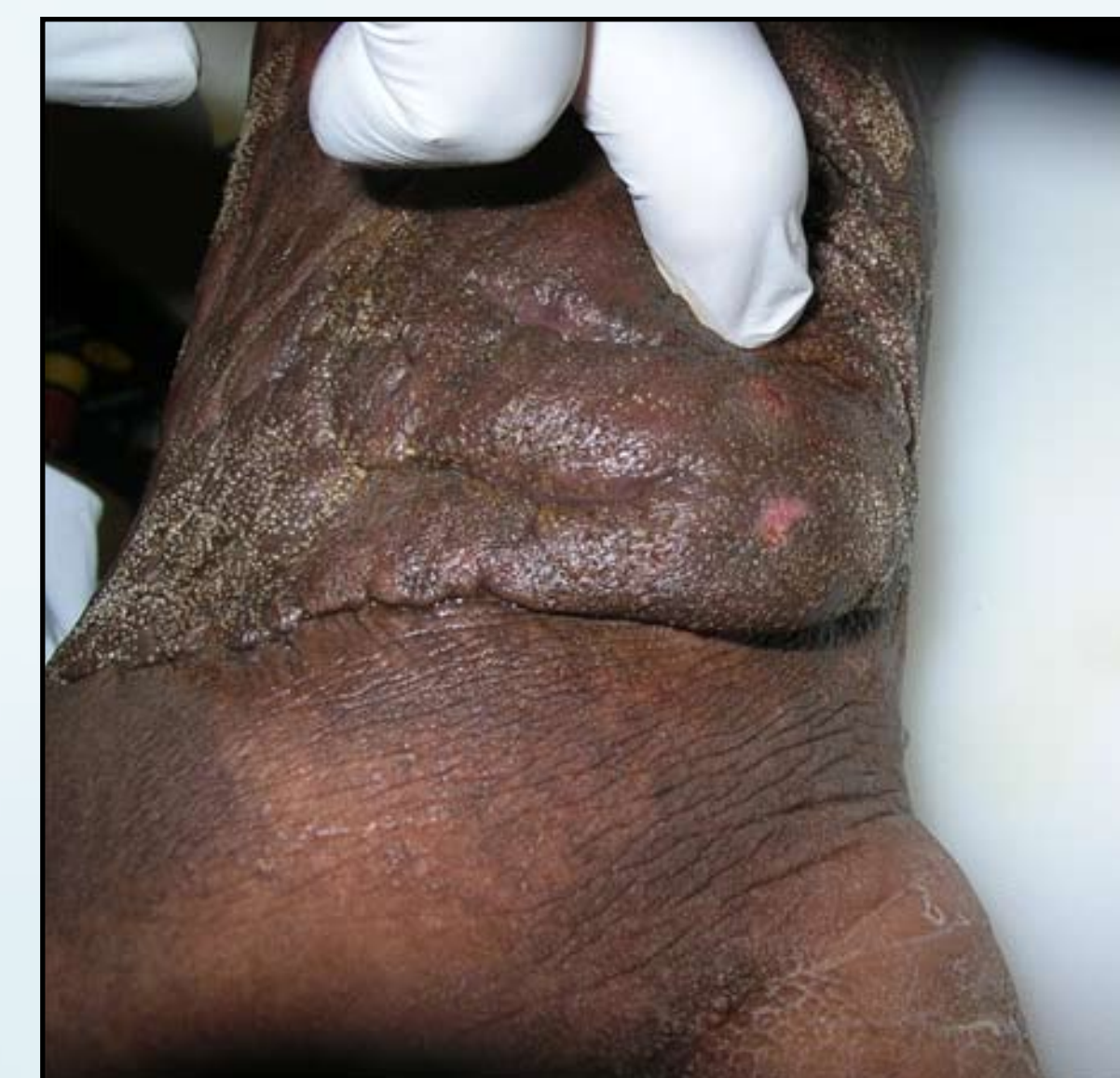
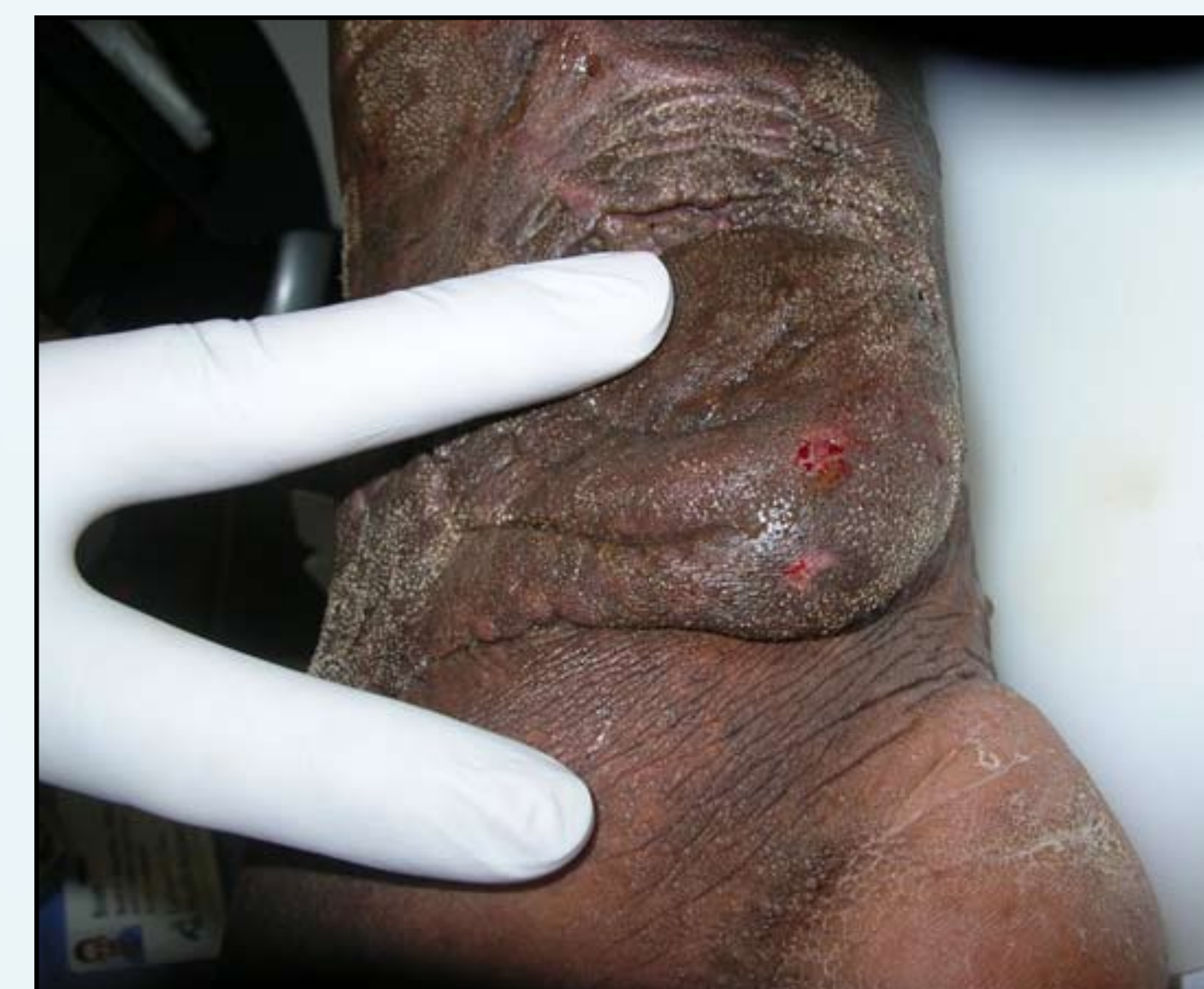
Figure 4b.



Results:

Immediately after the treatments diffuse weeping of lymphedema fluid was noted (see Figures 3,4a, 4b). The weeping subsided 3-5 days after each treatment. Treatments were spaced 6-8 weeks apart. After 3 treatments, significant softening of the entire area was noted. In addition, the total circumference of the ankle decreased by 2cm without additional lymphedema therapy. The patient noted significant reduction in micro-injuries and time with open wounds in the area. (Figures 5,6,7)

3 Months After Treatment

Figure 5.

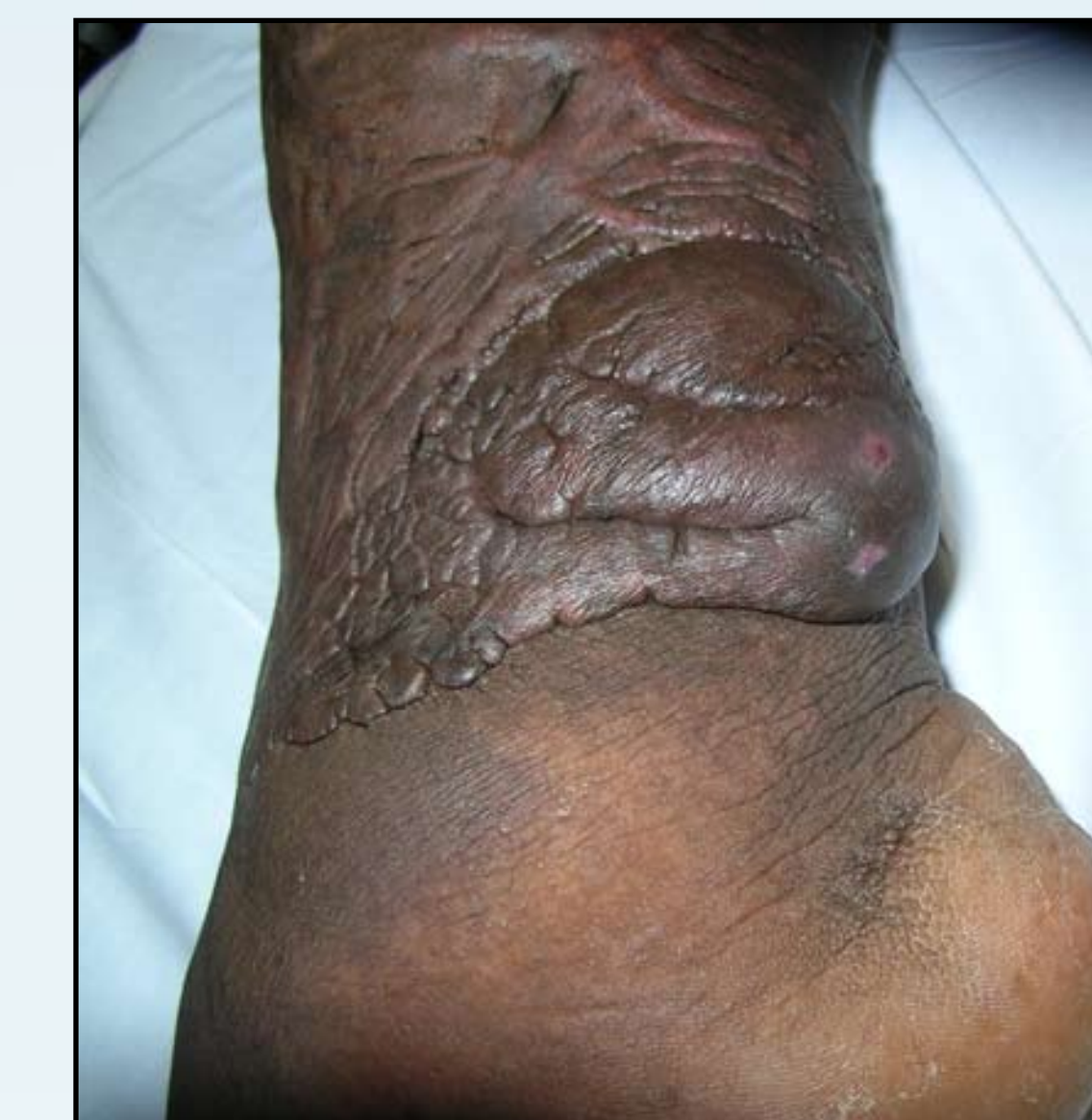

Figure 6.

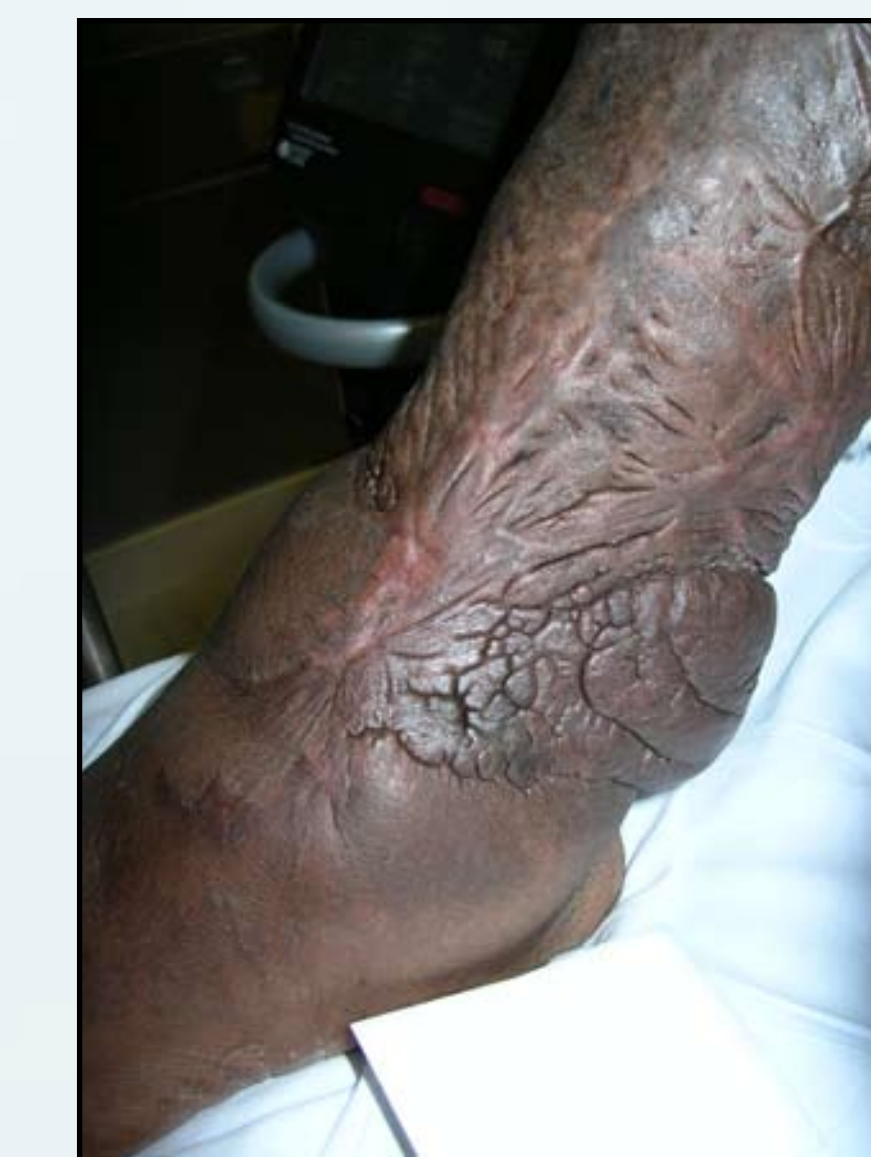
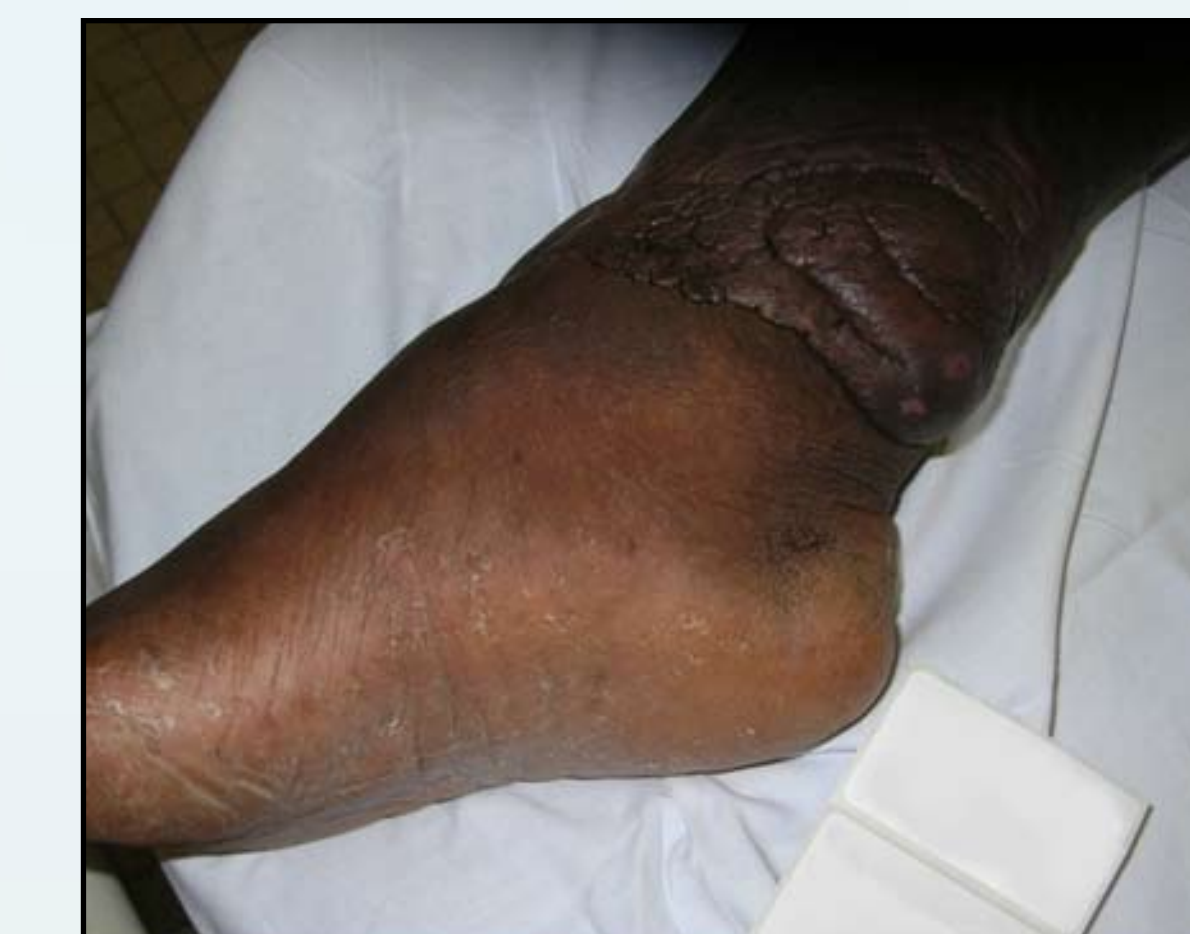
Figure 7.



Discussion:

There is no report in the literature about fractional CO₂ laser treatment of lymphedema or lymphedema caused by scarring. Total ablation with a CO₂ laser of post-radiation and oncologic surgery lymphedema of the vulva is currently published in the Oncol Letters 2015 April edition, available as Epublication, by Sopracordevole et al. as a last resort treatment (1). Fractional CO₂ laser treatment may be a promising tool to treat chronic lymphatic stasis disease with fibrotic changes by softening of the fibrosis (2) and immediate drainage of the edema fluid through the surface of the scar and may decrease the injury propensity of the affected limb, especially when the lower extremities are involved. Further and formal study is warranted.

References:

1. Sopracordevole F, Mancini F, Canzonieri V, Buttignol M, Giorda G, Ciavattini A. Laser CO₂ treatment for vulvar lymphedema secondary to gynecological cancer therapy: A report of two cases and review of the literature. *Oncol Lett*. 2015 Apr;9(4):1889-1892. Epub 2015 Feb 12.
2. Ozog DM, Liu A, Chaffins ML, Ormsby AH, Fincher EF, Chipps LK, Mi QS, Grossman PH, Pui JC, Moy RL. Evaluation of clinical results, histological architecture, and collagen expression following treatment of mature burn scars with a fractional carbon dioxide laser. *JAMA Dermatol*. 2013 Jan;149(1):50-7. doi: 10.1001/2013.jamadermatol.668.

© 2015 Lehigh Valley Health Network

A PASSION FOR BETTER MEDICINE.™

610-402-CARE LVHN.org