

# Pearls of Wisdom: A Case of Benzonatate Toxicity Resulting in Ventricular Fibrillation

Neiman Ramjattan DO

Lehigh Valley Health Network, Neiman.Ramjattan@lvhn.org

Raghunandan Muppidi MD

Lehigh Valley Health Network, Raghunandan.Muppidi@lvhn.org

Follow this and additional works at: <http://scholarlyworks.lvhn.org/medicine>



Part of the [Medical Sciences Commons](#)

---

## Published In/Presented At

Ramjattan, N., Muppidi, R. (May 2015). *Pearls of Wisdom: A Case of Benzonatate Toxicity Resulting in Ventricular Fibrillation*. Poster presented at: LVHN Residency and Fellowship Research Day, Lehigh Valley Health Network, Allentown, PA.

This Poster is brought to you for free and open access by LVHN Scholarly Works. It has been accepted for inclusion in LVHN Scholarly Works by an authorized administrator. For more information, please contact [LibraryServices@lvhn.org](mailto:LibraryServices@lvhn.org).



# Pearls of Wisdom: A Case of Benzonatate Toxicity Resulting in Ventricular Fibrillation

Neiman A. Ramjattan, DO, Raghunandan Muppidi, MD  
Lehigh Valley Health Network, Allentown, Pennsylvania

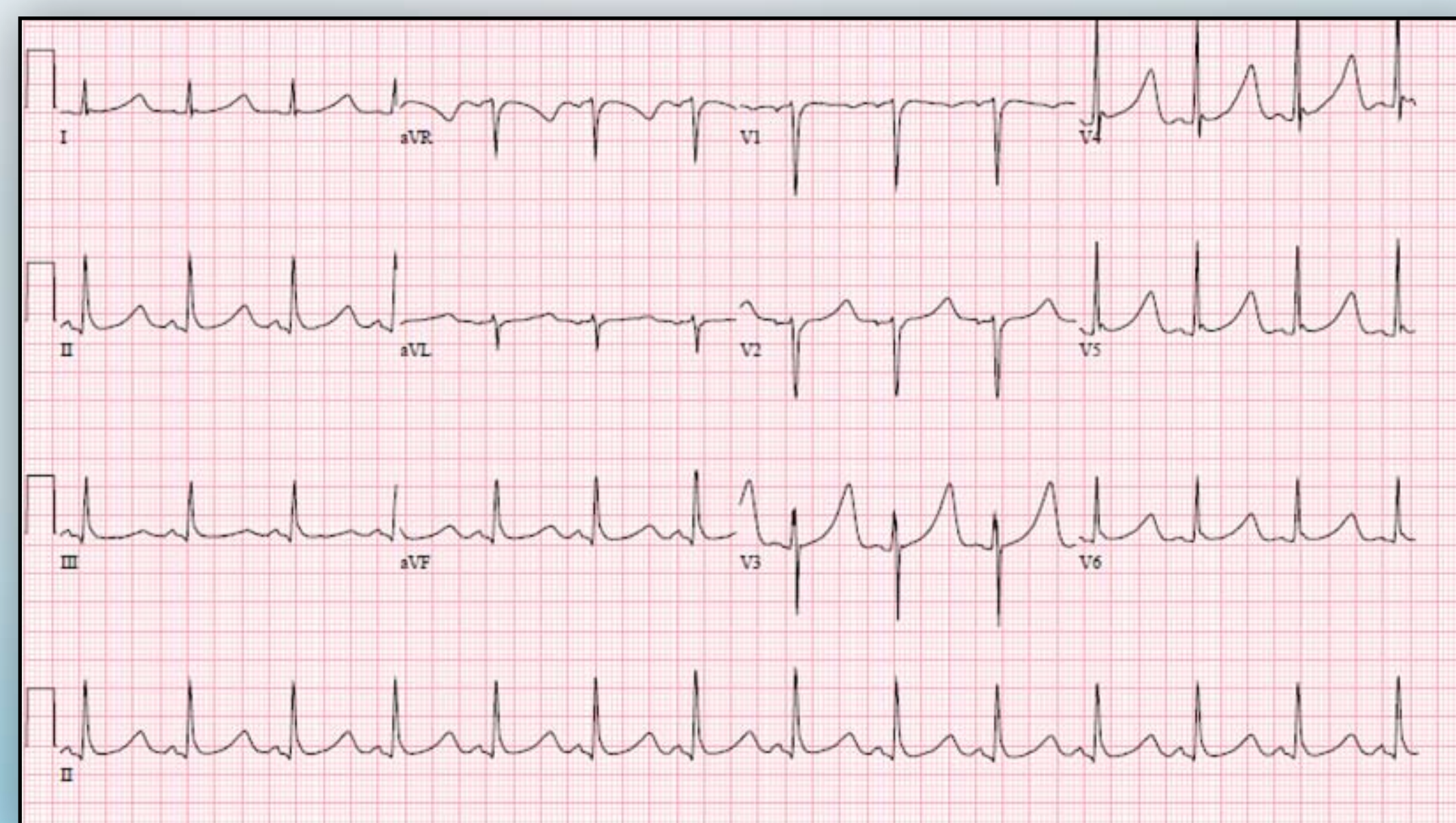
## Introduction

Cough is frequently encountered in clinical practice. Benzonatate is the only non-narcotic cough suppressant available for treatment of persistent cough. Symptoms of benzonatate toxicity can range from benign to life threatening, and treatment can prove to be a challenge given the lack of a specific antidote.

## Case

- A 17 year-old female was brought to the ED after admitting purposeful ingestion of twelve 200mg benzonatate capsules to her father.
- Upon arrival the patient was unresponsive with cardiac monitoring showing ventricular fibrillation. Return of spontaneous circulation was achieved per ACLS protocol.
- She was then treated with therapeutic hypothermia for 24 hours, bicarbonate infusions and intravenous lipids.
- Presenting EKG demonstrated a markedly prolonged QTc interval of 634. (Figure 1)
- Within 48 hours of arrival, the patient was successfully warmed and extubated with only mild retrograde amnesia as a residual deficit.

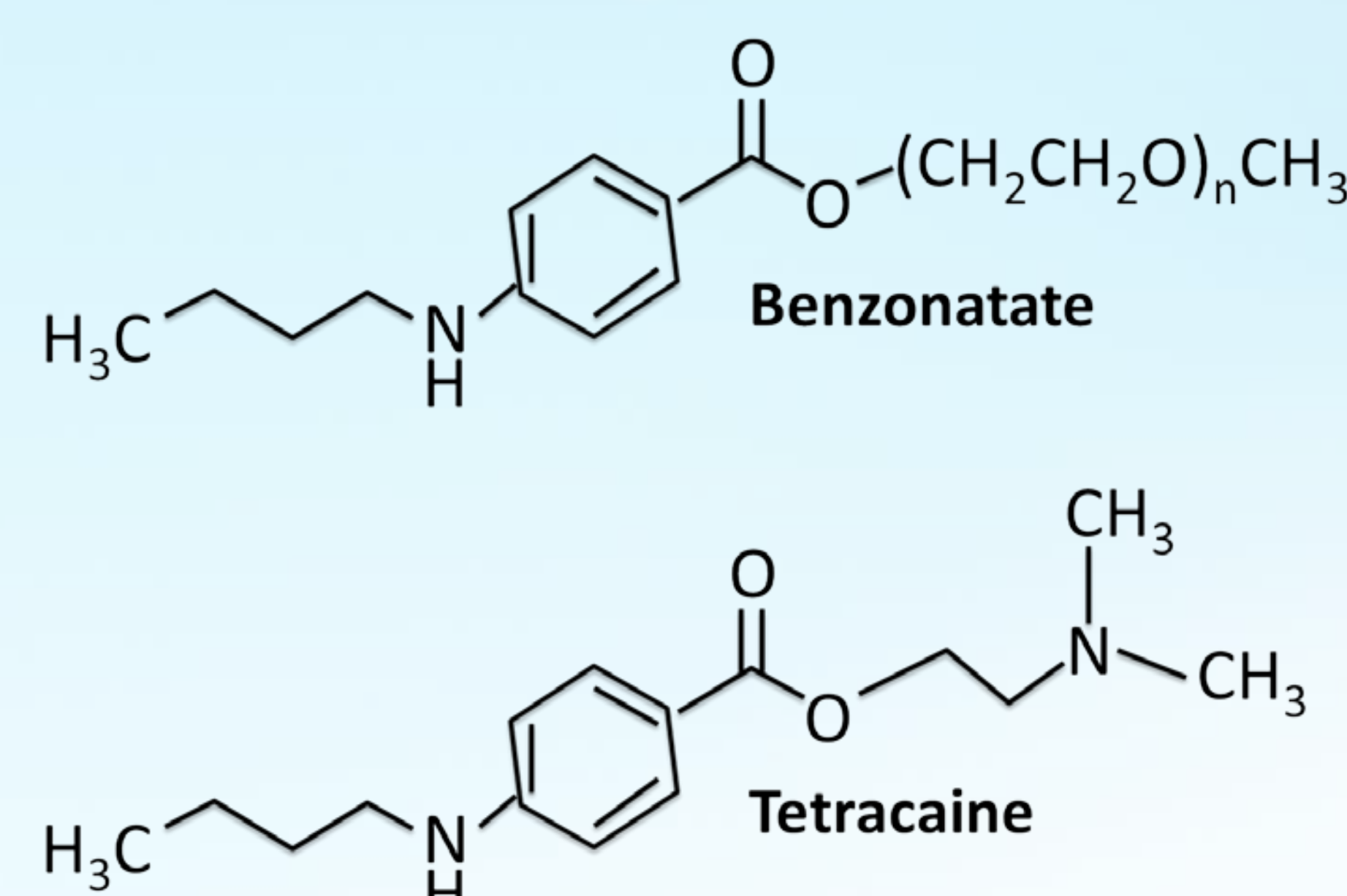
Figure 1: Presenting EKG.



## Discussion

- Benzonatate achieves its desired effect of cough suppression by means of anesthetizing stretch receptors in the lungs and neighboring tissues. Molecularly, it functions as a sodium channel blocker, similar to procaine and tetracaine. (Figures 2 and 3)

Figures 2 and 3: Benzonatate



- The toxicity margin has been reported as ranging broadly from as little as 200mg to upwards of 3600mg. (Table 1)
- Toxicity can manifest as tachycardia, agitation, seizures, coma, ventricular dysrhythmia, cardiac arrest, hypotension, and asystole. These symptoms have been reported to present within 15 minutes of ingestion. (Table 2)
- Therapeutic hypothermia can be indicated for unresponsive patients who survive VT/VF arrests.
- Benzonatate toxicity can cause profound metabolic acidosis, at times requiring bicarbonate infusions to maintain physiologic pH's.
- Intravenous lipid infusions can help bind the benzonatate molecule before it can seed tissues, thereby minimizing its duration of toxicity.
- The number of benzonatate prescriptions increased by 54% from 2004-2009, with 63% of those prescriptions coming from primary physicians. The low toxicity margin and rapidity of onset of toxicity suggests that more restraint and careful consideration should be exercised when prescribing benzonatate, especially in light of its potentially lethal side effect profile. (Figure 4)

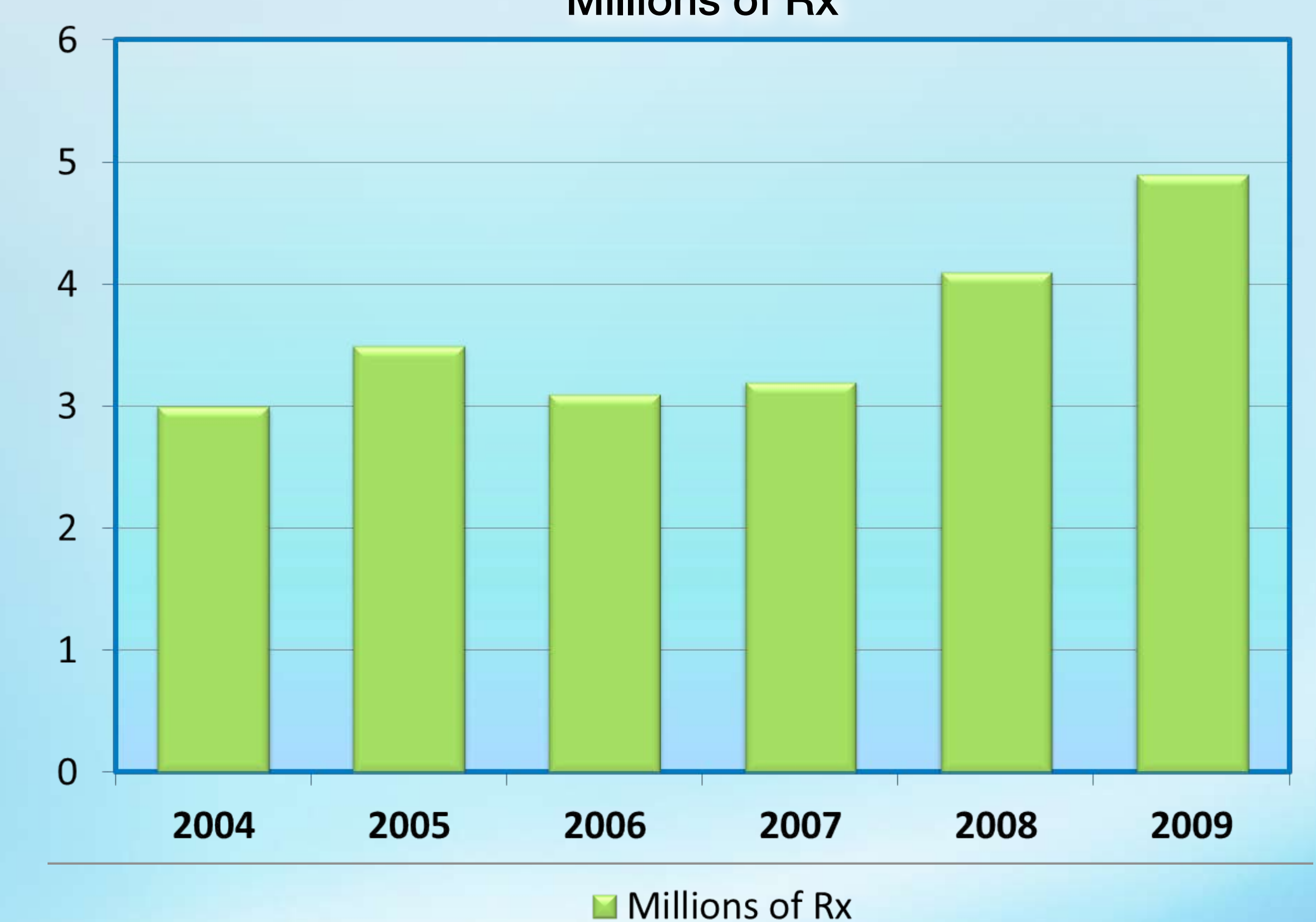
Table 1: Side Effects and Doses

Outcome	Number of Patients	Median Dose (mg)
Death	1	3000
Major	20	1410
Moderate	68	629
Minor	329	415

Table 2: Selected Side Effects

Moderate and Major Clinical Effects	% of Total
Tachycardia	1
Agitation	1
Seizure	1
Coma	0.6
Ventricular Arrhythmia	0.4
Cardiac Arrest	0.3
Hypotension	0.3
Asystole	0.2

Figure 4: Benzonatate Rx's 04'-09'  
Millions of Rx



## References:

1. Crouch, B. I.; Knick, K. A.; Crouch, D. J.; Matsumura, K. S.; Rollins, D. E. (1998). "Benzonatate overdose associated with seizures and arrhythmias". *Journal of toxicology. Clinical toxicology* 36 (7): 713-718. doi:10.3109/15563659809162620. PMID 9865240.
2. Cohan, J. A.; Manning, T. J.; Lukash, L.; Long, C.; Ziminski, K. R.; Conradi, S. E. (1986). "Two fatalities resulting from Tessalon (benzonatate)". *Veterinary and human toxicology* 28 (6): 543-544. PMID 3788039.
3. Pharmacotherapy. 2013 Jan;33(1):38-43. doi: 10.1002/phar.1153. Analysis of benzonatate overdoses among adults and children from 1969-2010 by the United States Food and Drug Administration.
4. McLawhorn MW1, Goulding MR, Gill RK, Michele TM. *J Med Toxicol.* 2010 Dec;6(4):398-402. doi: 10.1007/s13181-010-0086-6. Benzonatate Ingestion Reported to the National Poison Center Database System (NPDS).
5. Winter ML1, Spiller HA, Griffith JR. *J Emerg Med.* 2011 Aug;41(2):166-71. doi: 10.1016/j.jemermed.2009.08.027. Epub 2009 Nov 5. Cardiac arrest with residual blindness after overdose of Tessalon® (benzonatate) perles. Cohen V1, Jellinek SP, Stansfield L, Truong H, Baseluos C, Marshall JP.

© 2015 Lehigh Valley Health Network

A PASSION FOR BETTER MEDICINE.™

610-402-CARE LVHN.org