

Darkening and Eruptive Nevi During Treatment With Erlotinib

Stephen Hemperly DO

Lehigh Valley Health Network, Stephen.Hemperly@lvhn.org

Tanya Ermolovich DO

Lehigh Valley Health Network, Tanya.Ermolovich@lvhn.org

Nektarios I. Lountzis MD

Lehigh Valley Health Network, nektarios_i.lountzis@lvhn.org

Hina A. Sheikh MD

Lehigh Valley Health Network, hina_a.sheikh@lvhn.org

Stephen M. Purcell DO

Lehigh Valley Health Network, Stephen.Purcell@lvhn.org

Follow this and additional works at: <https://scholarlyworks.lvhn.org/medicine>



Part of the [Dermatology Commons](#), and the [Medical Sciences Commons](#)

Published In/Presented At

Hemperly, S., Ermolovich, T., Sheikh, H., Lountzis, N., Purcell, S. (2105, April 24). *Darkening and Eruptive Nevi During Treatment With Erlotinib*. Poster presented at: Atlantic Dermatological Society, Philadelphia, PA.

This Poster is brought to you for free and open access by LVHN Scholarly Works. It has been accepted for inclusion in LVHN Scholarly Works by an authorized administrator. For more information, please contact LibraryServices@lvhn.org.

Darkening and Eruptive Nevi During Treatment with Erlotinib (poster)

Stephen Hemperly DO

Lehigh Valley Health Network, Stephen.Hemperly@lvhn.org

Tanya Ermolovich DO

Lehigh Valley Health Network, Tanya.Ermolovich@lvhn.org

Nektarios I. Lountzis DO

Lehigh Valley Health Network, Nektarios_I.Lountzis@lvhn.org

Follow this and additional works at: <http://scholarlyworks.lvhn.org/medicine>



Part of the [Dermatology Commons](#), and the [Medical Sciences Commons](#)

Published In/Presented At

Hemperly, S., Ermolovich, T., & Lountzis, N. (2014, March 14). *Darkening and eruptive nevi during treatment with erlotinib*. Poster presented at: The Philadelphia Dermatological Society Conference, Philadelphia, PA.

This Poster is brought to you for free and open access by LVHN Scholarly Works. It has been accepted for inclusion in LVHN Scholarly Works by an authorized administrator. For more information, please contact LibraryServices@lvhn.org.

Darkening and Eruptive Nevi During Treatment With Erlotinib

Stephen Hemperly, DO, Tanya Ermolovich, DO, and Nektarios Lountzis, MD
Lehigh Valley Health Network, Allentown, Pennsylvania

Case Presentation:

Patient: 70 year-old Caucasian male.

History of Present Illness: Our patient developed eruptive nevi and darkening of his existing nevi three months after beginning erlotinib for treatment of non-small cell lung carcinoma. The patient's prior chemotherapeutic regimen was discontinued five weeks before starting erlotinib. A complete cutaneous exam after completion of these chemotherapeutic agents and prior to initiation of erlotinib was unremarkable for abnormally dark or eruptive nevi. Of note, the patient had not had a melanoma diagnosed since 2006. However, since the start of erlotinib the patient had ten biopsies performed on clinically suspicious dark nevi, two of which were favored to be melanoma in situ and one an atypical nevus.

Medical History/Surgical History: Non-small cell lung cancer (May 2012), invasive melanomas x3, atypical nevi, hypertension, diabetes, diverticulitis, gastroesophageal reflux disease, chronic obstructive pulmonary disease, left lower lobectomy and lymph node dissection (July 2012), pacemaker and defibrillator placement, gastric bypass, appendectomy, cholecystectomy

Medications: Erlotinib (started May 2013), lansoprazole, fosinopril, metformin, aspirin, simvastatin, niacin, nifedipine, bisoprolol fumarate/hydrochlorothiazide, furosemide

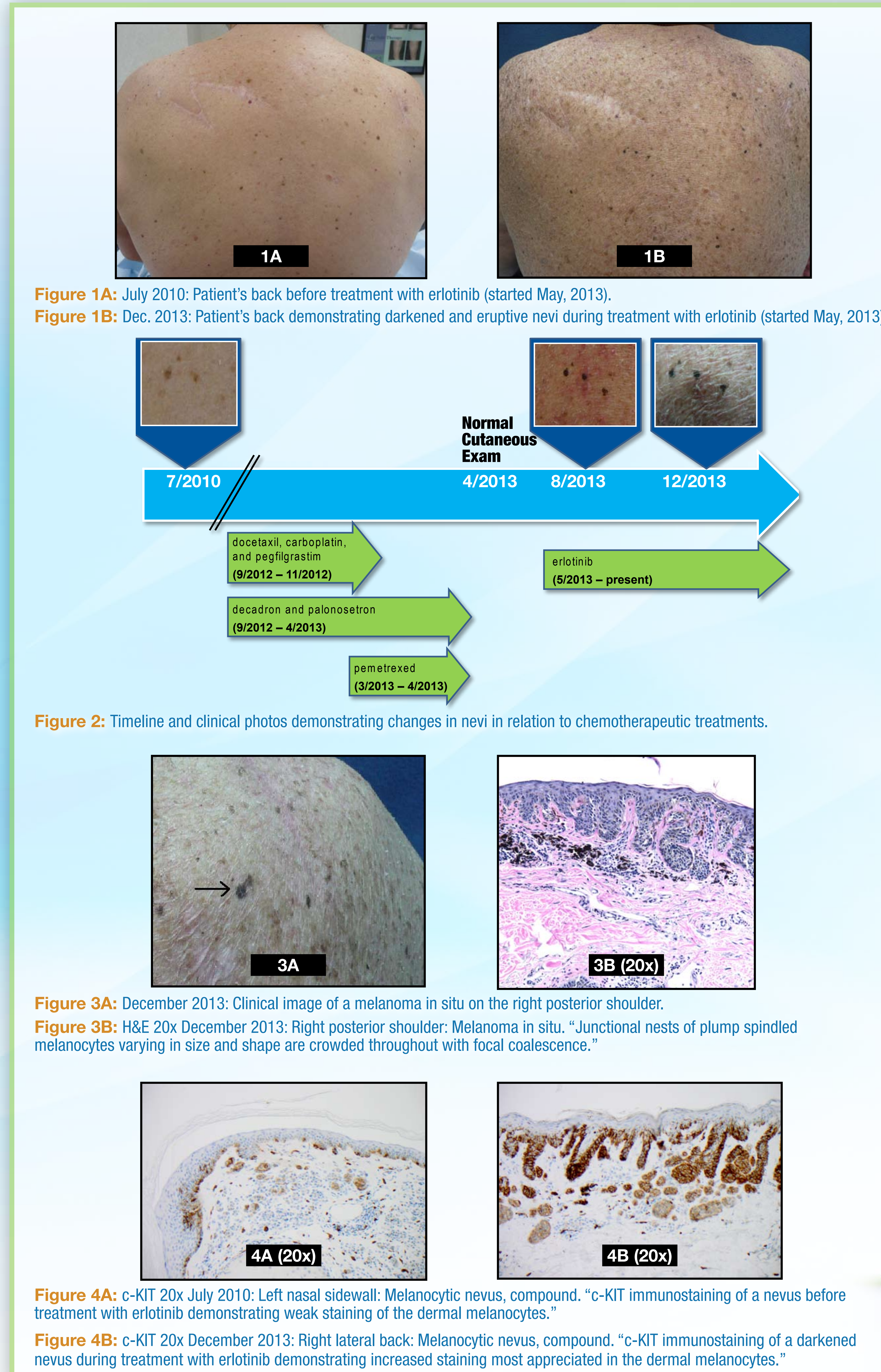
Previous Lung Cancer Treatments: Docetaxel, carboplatin, and pegfilgrastim (9/2012 - 11/2012), decadron and palonosetron (9/2012 - 4/2013), pemetrexed (3/2013 - 4/2013)

Physical Examination: Numerous dark brown to black macules on the trunk and bilateral extremities. Scattered papules and pustules with generalized xerosis on the trunk and extremities.

Studies: c-KIT immunostaining revealed a mild to moderate increase in intensity in nevi and melanomas post-darkening compared to similar pre-darkened lesions.

Biopsy: *Advanced Dermatology Associates, LTD (AD13-08457, 8/22/2013);* Right posterior shoulder: "Population of heavily pigmented, keratinocyte-sized melanocytes in coalescing, ill-defined, junctional and intraepidermal aggregates of varying morphology. Additionally, there is a population of solitary melanocytes scattered throughout the spinous zone."

Advanced Dermatology Associates, LTD (AD13-12842, 12/12/2013); Right posterior shoulder: "Junctional nests of plump spindled melanocytes varying in size and shape are crowded throughout with focal coalescence."



Discussion:

Erlotinib is a small molecule tyrosine kinase inhibitor that functions by blocking the intracellular portion of the epidermal growth factor receptor (EGFR). This blockade prevents tyrosine kinase phosphorylation and the activation of the mitogen-activated protein kinase (MAPK) signaling pathway involved in cell growth and proliferation. EGFR is found in the basal layer of the epidermis, sweat glands, and hair follicles, and is overexpressed in some cancers. Erlotinib is indicated in the treatment of non-small cell lung cancer and advanced stage pancreatic cancer. A number of cutaneous side effects have been reported including an acneiform eruption (63%), xerosis (7.7%), pruritus (3.8%), and paronychia (6%).

Eruptive nevi have been reported in one patient treated with erlotinib, and in seven patients treated with sorafenib, a multikinase inhibitor that also affects the MAPK pathway. Vemurafenib, a selective inhibitor of BRAF in the MAPK pathway, has been reported to produce dysplastic nevi, melanomas, eruptive nevi, and darkening of existing nevi. Changes in nevi were noted within a few months of initiating treatment with these medications. The effects of vemurafenib have been ascribed to a paradoxical up-regulation of MAPK, which has been well documented and demonstrated in vivo. Perhaps erlotinib has a similar potential to paradoxically up-regulate MAPK or other enzymes in the pathway, thus stimulating cellular proliferation and survival.

We decided to investigate c-KIT, a tyrosine kinase receptor that activates the MAPK pathway and is critical to the development and survival of melanocytes. Stimulation of c-KIT tyrosine kinase can also induce melanocyte proliferation and pigment production/melanogenesis. Activating mutations of c-KIT have been described in some cases of melanoma. In our patient, c-KIT immunostaining revealed a mild to moderate increase in intensity in nevi and melanomas post-darkening compared to similar pre-darkened lesions. Increased expression of c-KIT, possibly reactive to downstream inhibition of the MAPK pathway from erlotinib, could be implicated in our case of eruptive nevi.

To our knowledge, this is the first reported case of darkening of existing nevi, eruptive nevi, and melanoma in situ during treatment with erlotinib. The timeline and clinical similarities to previous reports of changes in nevi with other agents affecting the MAPK pathway provide support for erlotinib as the causative agent in our patient. We therefore suggest frequent full body cutaneous examinations to monitor for possible melanocytic atypia or development of malignant melanoma.

References:

- 1 Chu E, Wanat K, Miller C, Seykora J, Rosenbach M, Amaravadi R, Fecher L, McGettigan S, Giles L, Schuchter L, Brose M. Diverse cutaneous side effects associated with BRAF inhibitor therapy: A clinicopathologic study. *J Am Acad Dermatol* 2012;67:1265-72.
- 2 Kiyohara Y, Yamazaki N, Kishi A. Erlotinib-related skin toxicities: Treatment strategies in patients with metastatic non-small cell lung cancer. *J Am Acad Dermatol* 2013;69:463-72.
- 3 Santiago F, Goncalo M, Reis J, Figueredo A. Adverse cutaneous reactions to epidermal growth factor receptor inhibitors: a study of 14 patients. *An Bras Dermatol* 2011;86:483-90.
- 4 Uhlenhake E, Watson A, Aronson P. Sorafenib induced eruptive melanocytic lesions. *Dermatol Online J* 2013;19:181-84.
- 5 Longley B, Tyrrell L, Lu S, Ma Y, Langley K, Ding T, Duffy T, Jacobs P, Tang L, Modlin I. Somatic c-KIT activating mutation in urticaria pigmentosa and aggressive mastocytosis: establishment of clonality in a human mast cell neoplasm. *Nat Genet*. 1996 Mar;12:312-4.

© 2014 Lehigh Valley Health Network

A PASSION FOR BETTER MEDICINE.™

Lehigh Valley Health Network

610-402-CARE LVHN.org