

Can your heart handle the spice: A case of acute myocardial infarction and left ventricular apical thrombus.

Mahek Shah MD

Lehigh Valley Health Network, Mahek.Shah@lvhn.org

Jalaj Garg MD

Lehigh Valley Health Network, jalaj.garg@lvhn.org

Brijesh Patel MD

Lehigh Valley Health Network, brijesh.patel@lvhn.org

Justin L. Guthier MD

Lehigh Valley Health Network, Justin_L.Guthier@lvhn.org

Ronald S. Freudenberger MD

Lehigh Valley Health Network, ron.freudenberger@lvhn.org

Follow this and additional works at: <https://scholarlyworks.lvhn.org/medicine>




Part of the [Medical Sciences Commons](#)

Published In/Presented At

Shah, M., Garg, J., Patel, B., Guthier, J., & Freudenberger, R. S. (2016). Can your heart handle the spice: A case of acute myocardial infarction and left ventricular apical thrombus. *International Journal Of Cardiology*, 215129-131. doi:10.1016/j.ijcard.2016.04.055.

This Article is brought to you for free and open access by LVHN Scholarly Works. It has been accepted for inclusion in LVHN Scholarly Works by an authorized administrator. For more information, please contact LibraryServices@lvhn.org.



Correspondence

Can your heart handle the spice: A case of acute myocardial infarction and left ventricular apical thrombus



Mahek Shah ^{*}, Jalaj Garg, Brijesh Patel, Justin Guthier, Ronald S. Freudenberger

Division of Cardiology, Lehigh Valley Hospital Network, Allentown, PA, United States

ARTICLE INFO

Article history:

Received 2 April 2016

Accepted 10 April 2016

Available online 14 April 2016

Keywords:

Marijuana

Synthetic cannabinoids

Myocardial infarction

Spice

Ventricular thrombus

Marijuana remains the commonest used illicit drug in the United States according to the 2013 National Survey on Drug Use and Health, particularly among youngsters [1]. In the survey, more than 10% of the people aged 12 years and above reported marijuana use within the prior one year [1]. Regular use of marijuana has been associated with short and long term cognitive impairment, altered brain development, proclivity for addiction, psychiatric manifestations to significant cardiovascular risk [2,3].

Delta 9-tetrahydrocannabinol (Δ^9 -THC) is the predominant psychoactive compound that interacts with the endocannabinoid system through CB1 and CB-2 cannabinoid receptors distributed throughout the body [4,5]. Interaction of Δ^9 -THC with these receptors has been speculated to cause most of the downstream cardiac effects. CB1 receptors may affect myocardial contractility and CB2 receptors may regulate post myocardial infarct inflammation [6,7]. THC is a partial agonist that binds to CB1 and CB2 receptors with equal affinity. In comparison, synthetic cannabinoids are full agonists with superior potency [8–10]. Use of synthetic cannabinoids has come to prominence in recent years as an alternative to marijuana due to its false marketing as being safe and being synthesized using naturally occurring herbal psychoactives [11]. It is sold under various names such as spice, K2, skunk, joker and black mamba. An important selling factor has been the fact that synthetic marijuana evades routine drug screens. Synthetic cannabinoids are currently classified under Schedule 1 controlled substances as per Federal legislation.

^{*} Corresponding author at: Division of Cardiology, Lehigh Valley Health Network, 1250 S Cedar Crest Blvd, Suite 300, Allentown, PA 18103, United States.

E-mail address: dr.mahekshah@yahoo.co.in (M. Shah).

Despite limited literature, experience with synthetic THC analogs has been negative with several reported cases of adverse events including death, psychosis and heart attacks [11–14]. We present the case of a young adult with chronic marijuana use and occasional use of spice who presented with an acute myocardial infarction and a left ventricular apical thrombus.

24-year-old male with no past history and family history presented to the hospital with sub-sternal chest pain that woke him up from sleep. He has a 10-pack year smoking history, with habitual marijuana use and recently used spice within the past week. He denies use of cocaine, amphetamines or other street drugs.

His initial electrocardiogram demonstrated normal sinus rhythm with no evidence of any ischemic changes. However, his cardiac troponin levels were elevated which peaked at 9.5 ng/ml. Other blood tests including basic metabolic panel, liver function tests and a lipid panel were within normal limits. A urine drug screen was positive for cannabinoids but negative for other drugs. A coronary angiogram revealed the presence of a discrete 70% calcified lesion in the proximal left anterior descending artery suspicious for thrombus and Thrombolysis in Myocardial Infarction (TIMI) grade 2 flow in the vessel (Image A). Manual thrombectomy was unsuccessful in dissolving the thrombus and the patient received a drug eluting stent at the site of the lesion with re-establishment of TIMI grade 3 flow post percutaneous coronary intervention.

A transthoracic echocardiogram with contrast demonstrated normal biventricular systolic function and the presence of a left ventricular apical thrombus with apical hypokinesis (Image B). The patient was started on therapeutic anticoagulation with an enoxaparin bridge to warfarin and eventually discharged home.

The patient continued to follow closely with cardiology as outpatient. Antithrombin III, prothrombin time, partial thromboplastin time, fibrinogen, homocysteine, protein S, protein C, and plasminogen activator inhibitor-1 levels were in the normal range. Lupus anticoagulant, factor V Leiden, and prothrombin G20210A tests were negative. The patient denied further episodes of chest discomfort on follow-up and quit cigarette smoking.

We believe that this is the first case in an adult where the use of marijuana in addition to spice was associated with the development of a non-ST elevation myocardial infarction (NSTEMI) and left ventricular thrombus.

In the Determinants of Myocardial Infarction Onset Study, Mittleman et al. showed that marijuana use was responsible for triggering heart attacks [15]. They estimated a 4.8-fold increase in risk of myocardial

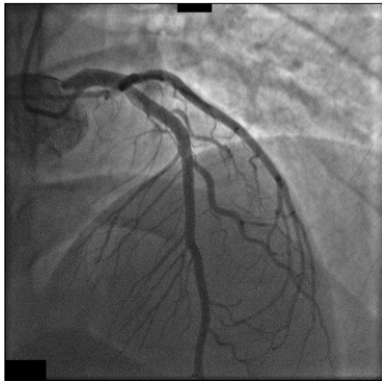


Image A. Coronary angiogram revealing obstructive thrombus in the proximal left anterior descending artery.

infarction (MI) over baseline within the first hour after marijuana consumption that rapidly decreased with time. Nawrot et al. performed a comparative assessment and evaluated the relative impact of various MI triggers. They found marijuana to be among the top three trigger following cocaine and heavy meal consumption [16]. The overall effect of THC on the cardiovascular system and its association with heart attacks is likely related to activation of the sympathetic cascade with simultaneous inhibition of parasympathetic activity [17]. This results in increase in heart rate, supine blood pressure and cardiac output leading to an elevated myocardial oxygen demand but a simultaneous decrease in the oxygen carrying capacity of the blood due to production of carboxyhemoglobin with smoking. Other potentially harmful cardiovascular effects reported include postural hypotension, altered peripheral vascular response, development of arteritis and vasoconstriction [18–25]. A decrease in angina threshold measured by exercise time to angina was more prominent following smoking a single marijuana cigarette compared to a high nicotine cigarette [18]. Chronic users also have an attenuated heart rate and rate pressure product compared to regular users [26] and a rebound increase in blood pressure on cessation of use [27]. Interestingly, a lot of the marijuana related literature dates back to four decades ago when concentration of THC was several-fold lesser compared to marijuana sold today and an additional dose related risk cannot be ignored [28].

The effect of THC on platelets and coagulation is not well known. Platelet membrane preparations have been shown to contain CB1 and

CB2 receptors, with conflicting evidence of THC induced platelet aggregation [29,30]. In addition to its effect on the autonomic nervous system, THC may result in inflammatory response within the coronaries resulting in platelet activation, production of reactive oxygen species, and increased factor VII activity causing endothelial damage and thrombus formation with no significant coronary obstruction [31–33]. A study by Heiden et al. demonstrated that oral THC might be linked to minimally elevated factor VII levels in the absence of clinically demonstrable effects on coagulation in healthy males [34]. No clear link between THC and thrombus formation has been demonstrated clinically. Development of a left ventricular thrombus is more common following anterior myocardial infarction with increased risk for thrombo-embolic events, which may have been the etiology in our patient [35].

Use of spice has also been linked to the development of ST-segment elevation myocardial infarction (STEMI) in teenagers with no obstructive coronary artery disease on subsequent angiogram [12]. In another case, a 56 year old man with pre-existing coronary artery disease had a sudden cardiac arrest following use of spice [14].

JWH-018 was one of the active psychoactive components found in spice initially. Since then, other THC analogs such as JWH-073, HU-210, JWH-200, JWH-250, JWH-398, and JWH-081 have been synthesized and marketed. Government prohibition of these analogs has been challenging due to their interchangeable use [36] and the fact that chemical analyses of synthetic marijuana products reveal more than just one of these synthetic cannabinoids in a single mixture. Analyses of the herbs yield variable results making it difficult to verify the exact contents of the mixtures. Overall, the cardiovascular effects of K2 are poorly documented and remain largely unknown.

In the year 2015 through September, the American Association of Poison Control Centers had received 6310 reports of exposure to synthetic cannabinoids compared to 2668 in 2013 and 3680 in 2014 [37]. In the United States, Pennsylvania received the 4th highest number of synthetic cannabinoid related calls in 2015 following Mississippi, New York and Texas. A rapid heart rate was among the commonest symptoms reported with use of these substances with more than 15 related deaths already in the first five months of 2015.

Several cases of acute coronary syndromes associated with marijuana including STEMI have been reported in young patients with minimal risk factors. As in our case, there may be a higher incidence of angiographically demonstrated left anterior descending thrombus similar to prior reports [38,39]. Despite a lack of literature in this regard, in most cases of MI it is hypothesized that the direct and indirect hemodynamic stressors discussed above and their interaction with atherosclerotic plaques with down-stream plaque rupture and thrombosis may be the causative event. A multifactorial approach explains why marijuana may put patients at a higher risk for MIs, which is further exacerbated with concurrent cigarette smoking and use of other drugs such as cocaine and in the case of our patient synthetic marijuana.

Though a specialized toxicology screen for synthetic cannabinoids was not performed in our patient, smoking marijuana and K2 in close proximity to his myocardial infarction were held responsible for the event. It is vital to inquire regarding use of marijuana and synthetic analogs during medical history in addition to counseling regarding responsible drug use and potential for abuse. Health care providers should be on alert for drug-induced toxicities despite negative drug screen and report suspicious cases. Education for parents, health care workers, and adolescents about the potential health risks from using these products is essential. Further research is needed to evaluate the clinical effects of synthetic cannabinoids.

Conflict of interest

The authors report no conflict of interest.

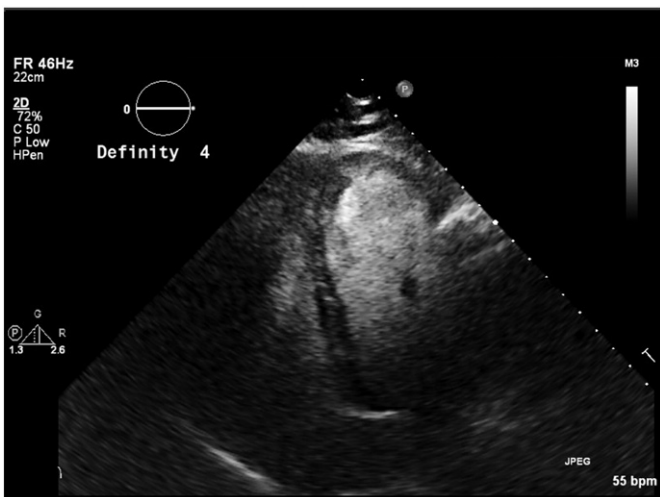

Image B. Apical 4-chamber view on 2D echocardiogram following intravenous definity contrast demonstrating apical thrombus.

References

- [1] Center for Behavioral Health Statistics and Quality, National Survey on Drug Use and Health, Substance Abuse & Mental Health Services Administration, Rockville, MD, 2013.
- [2] Volkow, et al., Adverse health effects of marijuana use, *N. Engl. J. Med.* 370 (June 2014) 2219–2227.
- [3] Jouanjus, et al., Cannabis use: signal of increasing risk of serious cardiovascular disorders, *J. Am. Heart Assoc.* (2014).
- [4] ElSohly, et al., Chemical constituents of marijuana: the complex mixture of natural cannabinoids, *Life Sci.* 78 (5) (December 2005) 539–548.
- [5] Nocerino, et al., Cannabis and cannabinoid receptors, *Fitoterapia* 70 (1) (August 2000) S6–12.
- [6] A. Bonz, M. Laser, S. Kullmer, S. Kniesch, J. Babin-Ebell, V. Popp, et al., Cannabinoids acting on CB1 receptors decrease contractile performance in human atrial muscle, *J. Cardiovasc. Pharmacol.* 41 (4) (2003) 657–664.
- [7] M. Zubrzycki, A. Liebold, A. Janecka, M. Zubrzycka, A new face of endocannabinoids in pharmacotherapy. Part I: protective role of endocannabinoids in hypertension and myocardial infarction, *Can. J. Physiol. Pharmacol.* 65 (2) (2014) 171–181.
- [8] Clemson University, Department of Chemistry, John W. Huffman, 2015 Available at: <http://www.clemson.edu/ces/departments/chemistry/people/faculty/huffman.html> Accessed October 26.
- [9] I. Vardakou, C. Pistos, Ch. Spiliopoulou, Spice drugs as a new trend: mode of action, identification and legislation, *Toxicol. Lett.* 197 (3) (2010) 157–162.
- [10] V. Auwärter, S. Dresen, W. Weinmann, M. Müller, M. Pütz, N. Ferreirós, Spice and other herbal blends: harmless incense or cannabinoid designer drugs? *J. Mass Spectrom.* 44 (5) (2009) 832–837.
- [11] Seely, et al., Spice drugs are more than harmless herbal blends: a review of the pharmacology and toxicology of synthetic cannabinoids, *Prog. Neuro-Psychopharmacol. Biol. Psychiatry* 39 (2) (December 2011) 234–243.
- [12] Mir, et al., Myocardial infarction associated with use of the synthetic cannabinoid K2, *Pediatrics* 128 (6) (Dec 2011), e1622–7.
- [13] Hermans-Claussen, et al., Acute toxicity due to the confirmed consumption of synthetic cannabinoids: clinical and laboratory findings, *Addict.* 108 (3) (March 2013) 534–544.
- [14] Ibrahim, et al., A unique case of cardiac arrest following K2 abuse, *Case Reports in Cardiology* 2014 (2014), 120607 3 pages.
- [15] M.A. Mittleman, R.A. Lewis, M. Maclure, J.B. Sherwood, J.E. Muller, Triggering myocardial infarction by marijuana, *Circulation* 103 (23) (2001) 2805–2809.
- [16] T.S. Nawrot, L. Perez, N. Kunzli, E. Munters, B. Nemery, Public health importance of triggers of myocardial infarction: a comparative risk assessment, *Lancet* 377 (9767) (2011) 732–740.
- [17] P. Beaconsfield, J. Ginsburg, R. Rainsbury, Marijuana smoking. cardiovascular effects in man and possible mechanisms, *N. Engl. J. Med.* 287 (5) (1972) 209–212.
- [18] W.S. Aronow, J. Cassidy, Effect of smoking marijuana and of a high-nicotine cigarette on angina pectoris, *Clin. Pharmacol. Ther.* 17 (1975) 549–554.
- [19] J.L. Weiss, A.M. Watanabe, L. Lemberger, N.R. Tamarkin, P.V. Cardon, Cardiovascular effects of delta-9-tetrahydrocannabinol in man, *Clin. Pharmacol. Ther.* 13 (5) (1972) 671–684.
- [20] R. Charles, S. Holt, N. Kirkham, Myocardial infarction and marijuana, *Clin. Toxicol.* 14 (4) (1979) 433–438.
- [21] S. Johnson, E.F. Domino, Some cardiovascular effects of marijuana smoking in normal volunteers, *Clin. Pharmacol. Ther.* 12 (1971) 762–768.
- [22] L. Bachs, H. Mørland, Acute cardiovascular fatalities following cannabis use, *Forensic Sci. Int.* 124 (2–3) (2001) 200–203.
- [23] A. Aryana, M. Williams, Marijuana as a trigger of cardiovascular events: speculation or scientific certainty? *Int. J. Cardiol.* 118 (2) (2007) 141–144.
- [24] K.J. Mukamal, M. Maclure, J.E. Muller, M.A. Mittleman, An exploratory prospective study of marijuana use and mortality after acute myocardial infarction, *Am. Heart J.* 155 (3) (2008) 465–470.
- [25] Basnet, et al., Coronary vasospasm in an adolescent resulting from marijuana use, *Pediatr. Cardiol.* 30 (4) (May 2009) 543–545.
- [26] L.L. Ponto, D.S. O'Leary, J. Koeppel, R.I. Block, G.L. Watkins, J.C. Richmond, et al., Effect of acute marijuana on cardiovascular function and central nervous system pharmacokinetics of [(15)O]water: effect in occasional and chronic users, *J. Clin. Pharmacol.* 44 (7) (2004) 751–766.
- [27] R. Vandrey, A. Umbricht, E.C. Strain, Increased blood pressure after abrupt cessation of daily cannabis use, *J. addict. med.* 5 (1) (2011) 16–20.
- [28] McLaren, et al., Cannabis potency and contamination: a review of the literature, *Addict.* 103 (7) (July 2008) 1100–1109.
- [29] Z. Dahdouh, V. Roule, T. Lognoné, R. Sabatier, G. Grollier, Cannabis and coronary thrombosis: what is the role of platelets? *Platelets* 23 (2012) 243–245.
- [30] E. Deusch, H.G. Kress, B. Kraft, S.A. Kozek-Langenecker, The procoagulatory effects of delta-9-tetrahydrocannabinol in human platelets, *Anesth. Analg.* 99 (2004) 1127–1130.
- [31] E. Tatli, M. Yilmaztepe, G. Altun, A. Altun, Cannabis induced coronary artery thrombosis and acute anterior myocardial infarction in a young man, *Int. J. Cardiol.* 120 (2007) 420–422.
- [32] S. Dwivedi, V. Kumar, A. Aggarwal, Cannabis smoking and acute coronary syndrome: two illustrative cases, *Int. J. Cardiol.* 128 (2008) e54–e57.
- [33] A.C. Linsday, R.A. Foale, O. Warren, J.A. Henry, Cannabis as a precipitant of cardiovascular emergencies, *Int. J. Cardiol.* 104 (2005) 230–232.
- [34] Heiden, et al., Effect of oral delta-9-tetrahydrocannabinol on coagulation, *Thromb. Res.* 17 (6) (March 1980) 885–889.
- [35] Stokman, et al., Left ventricular thrombus, *Curr. Treat. Options in Cardiovasc. Med.* 3 (6) (December 2001) 515–521.
- [36] R. Lindigkeit, A. Boehme, I. Eiserloh, M. Luebbecke, M. Wiggermann, L. Ernst, T. Beuerle, Spice: a never ending story? *Forensic Sci. Int.* 191 (1) (Oct. 2009) 58–63.
- [37] American Association of Poison Control Centers data for synthetic cannabinoids Available at <http://www.aapcc.org/alerts/synthetic-cannabinoids/> (Last accessed Oct 26) 2015.
- [38] Karabulut, et al., ST segment elevation myocardial infarction due to slow coronary flow occurring after cannabis consumption, *Kardiol. Pol.* 68 (2010) 1266–1268.
- [39] I. Biyik, I.F. Aktürk, A.A. Yalcin, et al., PP-228 cannabis joint triggered recurrent anterior myocardial infarction in an adolescent taking dual-antiplatelet therapy, *Int. J. Cardiol.* 155 (1) (2012) 177–178.