

Epidermolytic Acanthomas of the Scrotum.

Claire O. Dorfman DO
Lehigh Valley Health Network, Claire.Dorfman@lvhn.org

Tanya Ermolovich DO
Lehigh Valley Health Network, Tanya.Ermolovich@lvhn.org

Follow this and additional works at: <https://scholarlyworks.lvhn.org/medicine>



Part of the [Medical Sciences Commons](#)

Let us know how access to this document benefits you

Published In/Presented At

Dorfman, C. O., Ermolovich, T. (2017, March 17). *Epidermolytic Acanthomas of the Scrotum*. Poster Presented at: Philadelphia Dermatological Society Meeting / Philadelphia College of Osteopathic Medicine, Philadelphia, PA.

This Poster is brought to you for free and open access by LVHN Scholarly Works. It has been accepted for inclusion in LVHN Scholarly Works by an authorized administrator. For more information, please contact LibraryServices@lvhn.org.

Epidermolytic Acanthomas of the Scrotum

Claire O. Dorfman, DO and Tanya Ermolovich, DO
Lehigh Valley Health Network, Allentown, PA

Case Presentation

Patient: 64 year-old Caucasian male.

History of Present Illness: The patient presented in August 2016 with multiple, new, asymptomatic growths located on the scrotum. He denied itching, pain or burning. The patient was treated with Imiquimod 5% cream 3 times per week. After 4 weeks of treatment, he developed erythema and irritation primarily on the bilateral inguinal creases and penile shaft, without significant erythema on the scrotum. Imiquimod was continued for a total of 10 weeks. There was little improvement of the scrotal lesions. Interestingly, the patient was treated for pruritus scroti from 2009 to 2011.

Medical/Surgical History: Hypertension, asthma, benign prostatic hyperplasia, rosacea, seborrheic dermatitis, folliculitis, basal cell carcinoma, tonsillectomy, appendectomy, wisdom tooth extraction

Family History: Hypertension, heart disease, asthma

Medications: Lisinopril-hydrochlorothiazide, aspirin, tamsulosin, rosuvastatin, ciclesonide inhaled, albuterol inhaled, pseudoephedrine, azelastine/fluticasone propionate nasal, doxycycline 20mg BID, ketoconazole 2% shampoo, ketoconazole 2% cream, metronidazole 0.75% gel, clindamycin 1% gel

Previous Treatment: Imiquimod 5% cream 3 times per week for 10 weeks total, hydrocortisone 2.5% cream, triple paste

Allergies: Sulfonamides

Physical Examination: Multiple tan to light pink flat-topped 2-3mm keratotic papules located on the scrotum.

Biopsy: *Advanced Dermatology Associates, LTD.* (AD16-09835, 8/29/2016) Left inferior scrotal sack: "Epidermolytic acanthoma. A verruca with epidermolytic hyperkeratosis may be considered. However, because the epidermolytic hyperkeratosis is the predominant feature, a diagnosis of epidermolytic acanthoma is rendered."

Reason for Presentation: Interest

Discussion

Epidermolytic acanthoma is a rare benign tumor that can appear in two varieties; an isolated form which was initially described in 1970, as well as a disseminated form described in 1973. Individual lesions appear as an asymptomatic tumor less than 1 cm in diameter with a verrucous surface. Epidermolytic acanthomas can occur anywhere on the body with a predilection for the trunk, although involvement of the genitalia has been increasingly reported. They present during adulthood, with no particular predilection for a particular race or gender.

Epidermolytic hyperkeratosis is a characteristic histopathologic feature consisting of compact hyperkeratosis and vacuolar degeneration of keratinocytes in the spinous and granular layers. These findings are also seen in bullous congenital ichthyosiform erythroderma, which is also known as epidermolytic hyperkeratosis (EHK), a genodermatosis caused by mutations in keratin 1 and keratin 10 genes. Therefore, it has been hypothesized that epidermolytic acanthomas may represent a localized variant of generalized EHK. However, recent studies have failed to find gene mutations associated with the isolated form.

The pathogenesis of epidermolytic acanthomas remains unclear. Both clinically and histopathologically, these lesions are often mistaken for verrucae and condyloma acuminata. Therefore, a viral etiology has also been considered. There has been little evidence of human papillomavirus DNA found in these lesions, although Jung et al. recently reported a case of multiple epidermolytic acanthomas on the scrotum associated with human papillomavirus 16. Other exogenous factors may play a role such as other viral infections, ultraviolet radiation, sunburn, immunosuppression, and trauma.

Treatment is not necessary unless the appearance or associated symptoms are particularly bothersome to the patient. Some treatment modalities include surgical excision or other destructive options such as cryotherapy. Jang et al. also reported a case of multiple epidermolytic acanthomas successfully treated with topical imiquimod, and Tan et al. reported effective treatment of associated pruritus with 0.1% tacrolimus ointment.

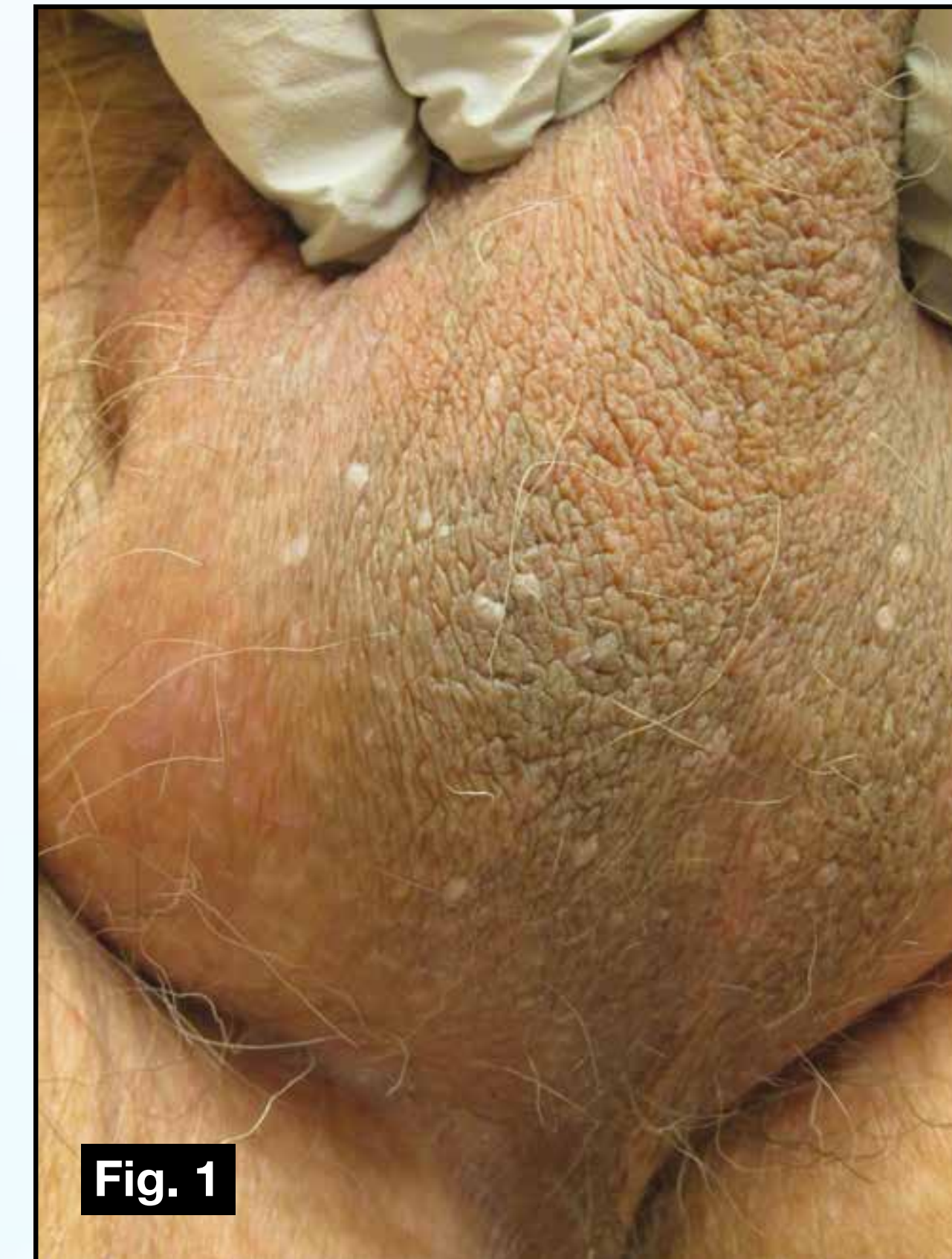

Figure 1: Multiple tan to light pink flat-topped 2-3mm keratotic papules located on the scrotum.

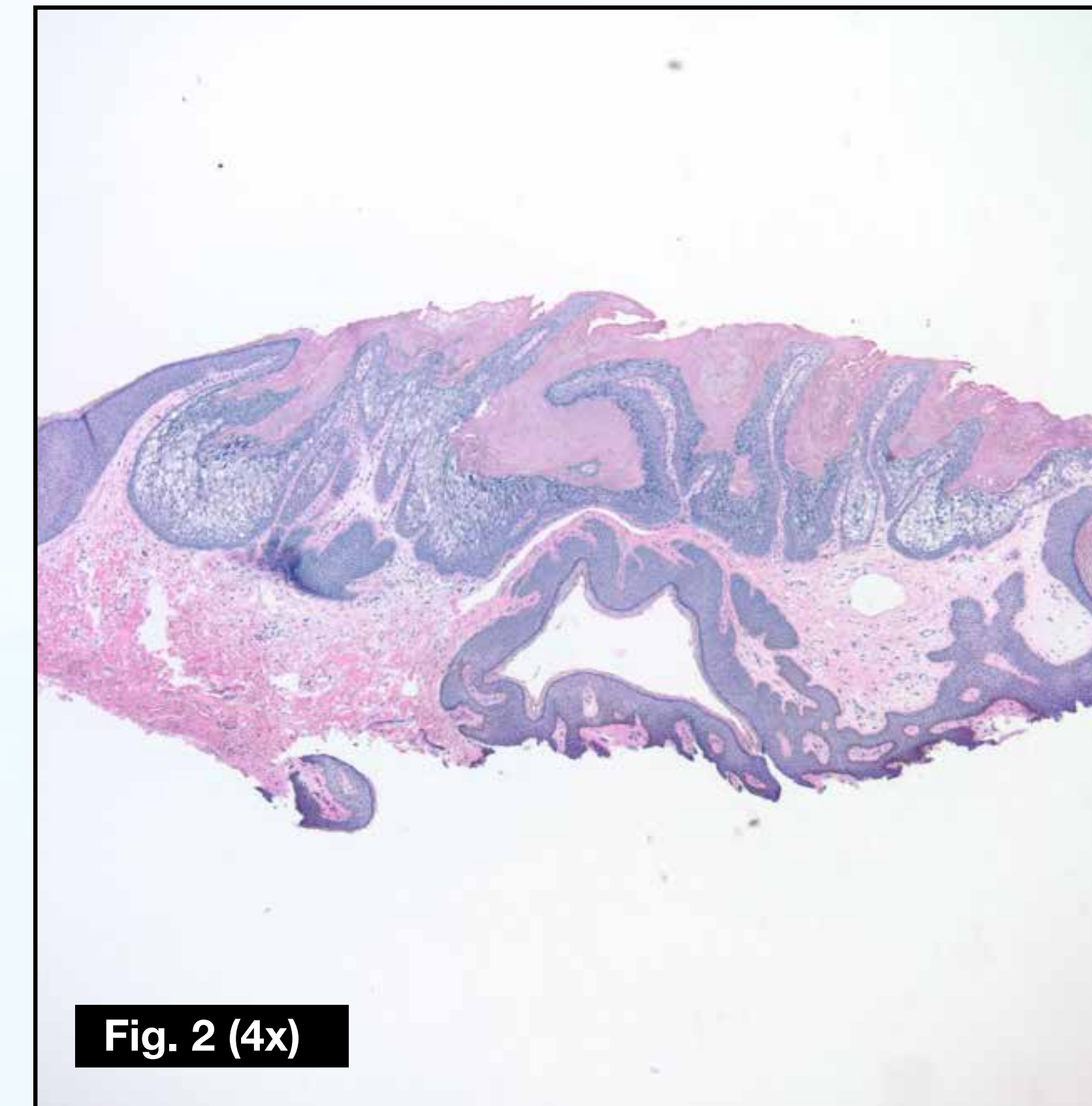


Figure 2: Low power (4X) view of the lesion showing papillomatosis and epidermolytic hyperkeratosis.

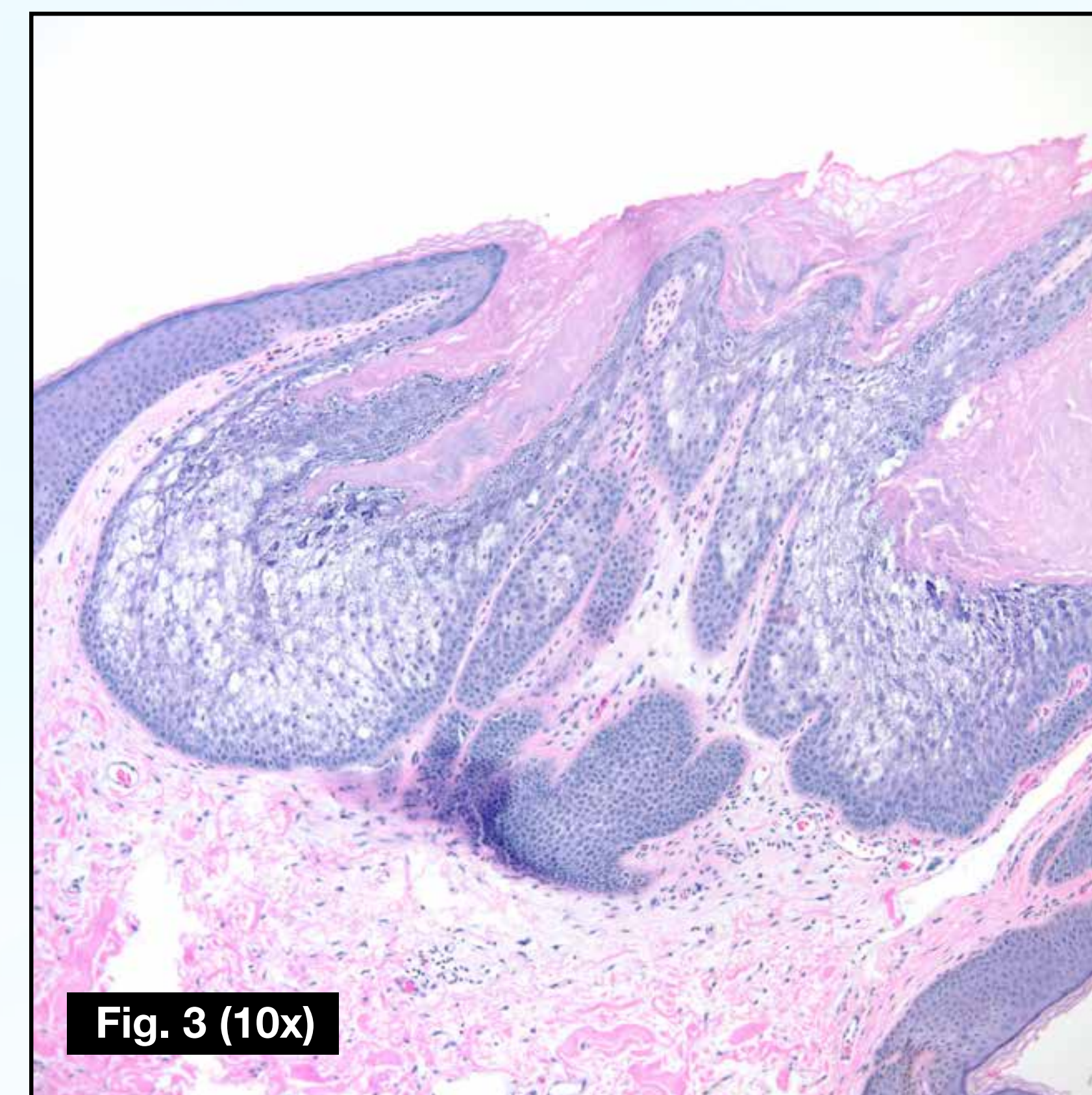


Figure 3: High power (10X) view showing compact hyperkeratosis, hypergranulosis, marked acanthosis and many vacuolated cells in the stratum granulosum and stratum spinosum.

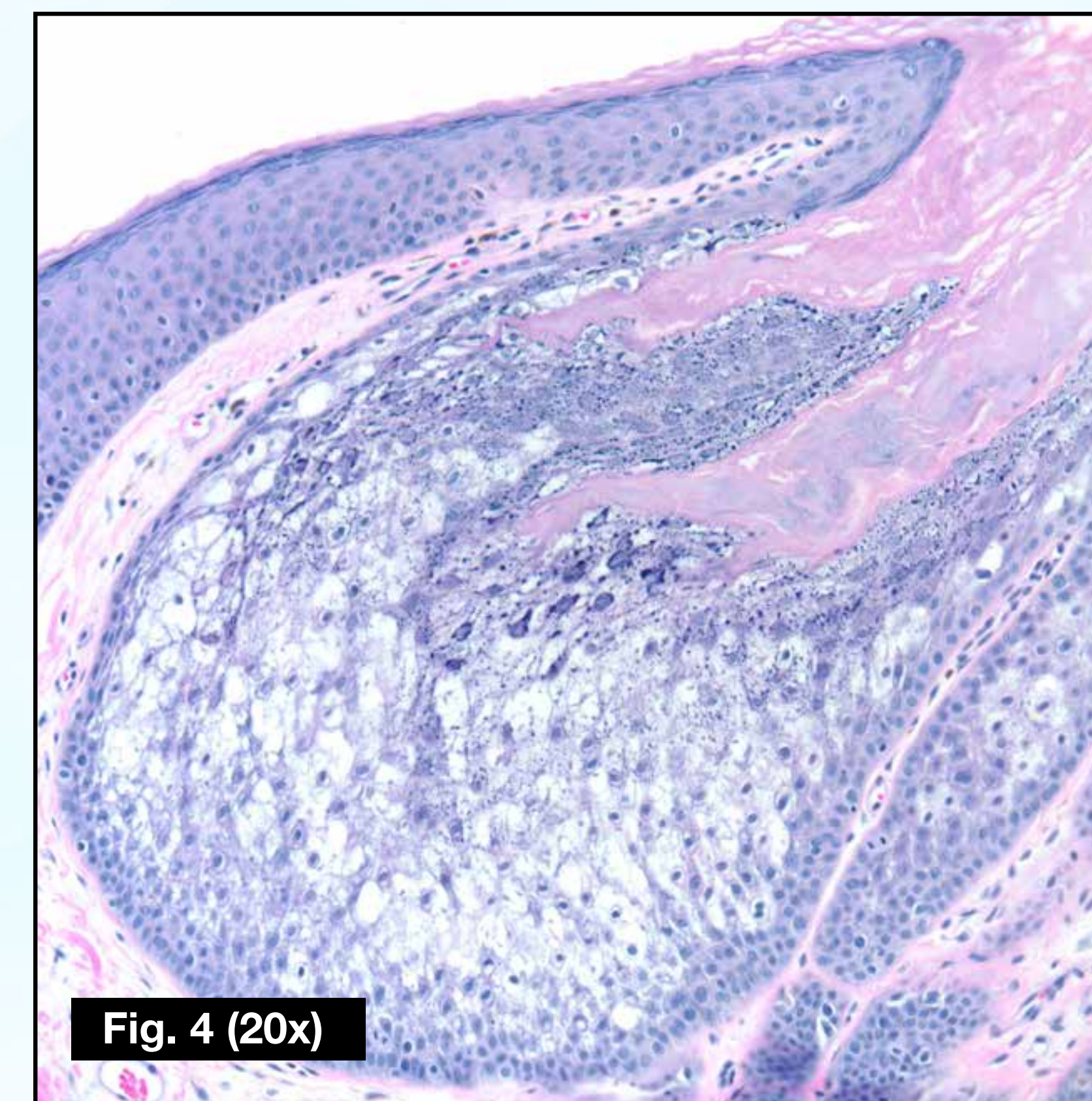


Figure 4: High power (20X) view showing vacuolated keratinocytes with irregular keratohyalin granules and ill-defined cell borders.

References:

1. Bogale SR, Chan CS, McIntire H, Hsu S. Epidermolytic acanthoma of the scrotum: A rare mimicker of condyloma acuminatum. *Dermatology Online Journal*. 2011;17(1).
2. Jang BS, et al. Multiple scrotal epidermolytic acanthomas successfully treated with topical imiquimod. *The Journal of Dermatology*. 2007;34(4):267-269.
3. Jung JM, et al. A case of multiple epidermolytic acanthoma of the scrotum: Is the human Papillomavirus a culprit? *Annals of Dermatology*. 2015;27(5):633.
4. Tan GF-L, Tan ES-T, Tey HL. Anogenital epidermolytic acanthomas: Effective treatment of pruritus with 0.1% tacrolimus ointment. *Dermatologic Therapy*. 2013;27(2):113-116.

© 2017 Lehigh Valley Health Network

610-402-CARE LVHN.org