Lehigh Valley Health Network
LVHN Scholarly Works

Department of Medicine

A Case of Pregnancy-associated Hemophagocytic Lymphohistiocytosis.

Misbat Chaudry MD
Lehigh Valley Health Network, Misbat.Chaudry@lvhn.org

Samuel Adediran MD
Lehigh Valley Health Network, Samuel.Adediran@lvhn.org

Follow this and additional works at: http://scholarlyworks.lvhn.org/medicine

Part of the Medical Sciences Commons

Published In/Presented At

Chaudry, M. Adediran, S. (2017 April 25). *A Case of Pregnancy-associated Hemophagocytic Lymphohistiocytosis*. Poster Presented at: Fellow/Resident Research day, LVH-CC, Allentown, PA.

This Poster is brought to you for free and open access by LVHN Scholarly Works. It has been accepted for inclusion in LVHN Scholarly Works by an authorized administrator. For more information, please contact LibraryServices@lvhn.org.

A Case of Pregnancy-associated Hemophagocytic Lymphohistiocytosis

Misbat Chaudry MD and Samuel Adediran MD

Division of Hematology Oncology, Department of Medicine, Lehigh Valley Health Network, Allentown, PA

INTRODUCTION

Hemophagocytic lymphohistiocytosis (HLH) is a syndrome of pathologic immune activation characterized by clinical signs and symptoms of extreme inflammation.[1]

HLH can be primary (familial) or secondary (acquired). Primary HLH is caused by genetic mutations affecting the cytotoxic function of T lymphocytes and natural killer (NK) cells and typically presents in young children. Secondary (acquired) HLH occurs in the setting of infectious, malignant, rheumatologic, or metabolic conditions.[2]

In familial HLH certain mutations cause impaired cytotoxic function and lead to an uncontrolled inflammatory response with the activation and expansion of interferon gamma (IFN g)–producing T cells. High levels of IFN g lead to macrophage activation and overproduction of proinflammatory cytokines, which can cause severe tissue damage and organ failure. Mutations have been found in the following genes: PRF1, UNC13D (MUNC13-4), STX11, STXBP2, and MUNC18-2.[2]

The diagnosis of HLH is often delayed due to the rarity of the disease, the complexity of diagnosis criteria and the varying patterns of presentation seen in different patients. Any five of a combination of eight clinical and laboratory criteria diagnose HLH based on HLH-2004 protocol (Table 1)[3]

Treatment of HLH involves induction treatment with chemoimmunotherapy as recommended in the HLH-94 protocol (figure 2), followed by maintenance treatment and hematopoietic stem cell transplant in those who have familiar, recurrent or HLH of unknown etiology.[3]

Despite its rarity we have seen about 5 cases of HLH at the Lehigh Valley Hospital over the past one year. We present here our first case of a pregnancy-associated HLH.

CASE

A 33-year-old G2P1 Caucasian female presented at 27 weeks gestation with flu-like symptoms. She reported one-week history of fever, chills, malaise and headache. A week before presentation, her two-year-old daughter had a febrile illness. A physical examination revealed an acutely ill female who was tachycardic (pulse 103) and mildly hypotensive (BP 96/53 mmHg). Initial laboratory evaluation revealed low platelet count (94 thou/cmm), elevated lactate dehydrogenase (623u/L), mild transaminitis and elevated total bilirubin (3.1mg/dL). Empiric antibiotics were started. Within a few hours of admission, she developed hypoxic respiratory failure requiring mechanical ventilation. A chest X-ray showed left lower lobe infiltrate suspicious of pneumonia. She became hemodynamically unstable. Her declining hemodynamic and respiratory status led to fetal distress. Therefore, emergent pre-term C-section was performed. Multi organ failure developed, and three pressors were soon required for hemodynamic support. Because of her worsening hypoxemia, veno-venous extra corporeal membrane oxygenation (ECMO) was instituted. Continuous renal replacement therapy (CRRT) was started for worsening renal failure. Evaluation for infection, including culture of bronchial lavage, was negative. Viral serology was positive for adenovirus and EBV IgG, but polymerase chain reaction (PCR) was negative. Further laboratory evaluations revealed elevated ferritin >10,000 ng/mL, LDH 1500 u/L and triglyceride 1981 mg/dL. She also developed disseminated intravascular coagulation (DIC) requiring multiple infusion of cryoprecipitate and platelet. Due to suspicion for HLH an urgent bone marrow biopsy was performed, and soluble CD 25 level was checked. Bone marrow pathology revealed hemophagocytosis (figure 3). Soluble CD 25 was elevated, 5980 pg/mL (normal < 1033 pg/mL). A computed tomography of the chest, abdomen and pelvis showed mild splenomegaly and no evidence of malignancy. She met HLH-2004 trial criteria with 6/8 findings for the diagnosis of HLH. After the diagnosis was established, treatment was started with corticosteroids (dexamethasone 10 mg/m2). Etoposide was initially held due to renal failure and elevated bilirubin. It was later started with 25% of the dose established in HLH 94 protocol. A week later, she was extubated. CRRT was switched to intermittent hemodialysis. By the time she received her third dose of etoposide bilirubin and liver enzymes had improved, therefore she received 50% of protocol dose. She recovered fully and completed the induction therapy two months after her initial presentation. She started maintenance therapy with pulse dexamethasone and etoposide which was later switched to tacrolimus after her ferritin level normalized. Clinically the patient is doing well, so is her newborn.

Table 1. Diagnostic Criteria for HLH Used in the HLH-2004 Trial

A	Pathologic mutations of PRF1, UNC13D, Munc18-2, Rab27a, STX11, SH2D1A, or BIRC4
B	**Five of the 8 criteria listed below are fulfilled** 1. Fever 38.5ºC 2. Splenomgealy 3. Cytopenias (affecting at least 2 of 3 lineages in the peripheral blood) a. Hemoglobin 9 g/dL (in infants 4 weeks: hemoglobin 10 g/dL) b. Platelets 100,000 c. Neutrophils 100 4. Hemophagocytosis in bone marrow, spleen, lymph nodes, or liver 5. Low or absent NK-cell activity 6. Ferritin 500 ng/mL

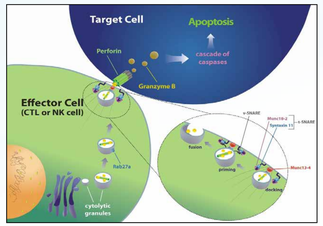

Figure 1: Mechanics of cytotoxic function revealed by HLH-associated gene mutations.

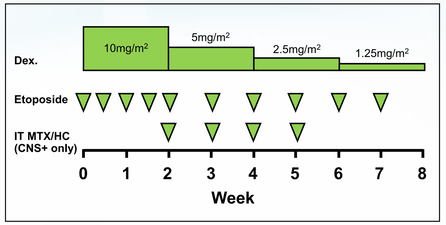

Figure 2: HLH-94 protocol for the treatment of HLH

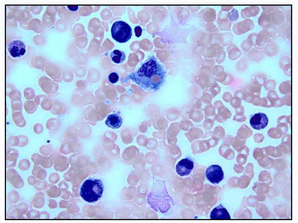

Figure 3: Bone marrow biopsy demonstrating hemophagocytosis

DISCUSSION

Hemophagocytic lymphohistiocytosis is a rare occurrence that is even rarer in pregnancy with only about 12 cases described in the English literature as at 2015.[4]

HLH is characterized by high mortality. In pregnancy, those who respond to treatments suffer obstetric complications and often require induced abortion or premature birth.

A large number of reported pregnancy-related HLH were triggered by viral infection: EBV, parvovirus, VZV, HSV-2.[5] In our patient, serology was positive for adenovirus IgG, but PCR was negative. It is likely that the HLH was induced by viral infection.

Disease-specific treatment for HLH based on HLH-94 protocol involves induction with dexamethasone and etoposide (HLH-94)[6]. Chemotherapy is toxic to the fetus and thus cannot be given in pregnancy. Corticosteroid alone or in combination with IVIG have been have been successfully used in some reported cases.[5]

It is of interest that in a few reported cases, patients' symptoms resolved and laboratory parameters improved after delivery, raising the assumption that pregnancy may increase risk in predisposed patients.[4] However, mutation analysis shows no evidence of familial HLH in our patient and hence she likely has no predisposition. In her HLH was probably triggered by viral infection (adenovirus) and her pregnancy status was of unknown risk.

In patients with known predisposition to HLH, recurrent disease, or no clear precipitating cause allogeneic bone marrow transplant is recommended. Maintenance therapy with dexamethasone pulses, cyclosporine daily, and etoposide should be considered after induction if stem cell transplant is not immediately feasible.[2]

Because it was not clear-cut that HLH in our patient was viral-induced, maintenance treatments initially with dexamethasone pulses and etoposide and later with tacrolimus were considered.

References:

1. Michael B. Jordan, Carl E. Allen, Sheila Weitzman, Alexandra H. Filipovich, Kenneth L. McClain. How I treat hemophagocytic lymphohistiocytosis. *Blood.* 2011 Oct 13; 118(15): 4041–4052.
2. Schram AM, Berliner N. How I treat hemophagocytic lymphohistiocytosis in the adult patient. *Blood.* 2015 May 7;125(19):2908-14.
3. Henter JI, Horne A, Aricó M, Egeler RM, Filipovich AH, Imashuku S, Ladisch S, McClain K, Webb D, Winiarski J, Janka G. HLH-2004: Diagnostic and therapeutic guidelines for hemophagocytic lymphohistiocytosis. *Pediatr Blood Cancer.* 2007 Feb;48(2):124-31.
4. Bachar Samra, Mohamad Yasmin, Sami Arnaout, and Jacques Azzi. Idiopathic Hemophagocytic Lymphohistiocytosis During Pregnancy Treated with Steroids Hematol Rep. 2015 Sep 23; 7(3): 6100.
5. Dunn T, Cho M, Medeiros B, Logan A, Ungewickell A, Liedtke M. Hemophagocytic lymphohistiocytosis in pregnancy: a case report and review of treatment options. *Hematology.* 2012 Nov;17(6):325-8.
6. Henter JI, Aricó M, Egeler RM, Elinder G, Favara BE, Filipovich AH, Gadner H, Imashuku S, Janka-Schaub G, Komp D, Ladisch S, Webb D. HLH-94: a treatment protocol for hemophagocytic lymphohistiocytosis. HLH study Group of the Histiocyte Society. *Med Pediatr Oncol.* 1997 May;28(5):342-7.

© 2017 Lehigh Valley Health Network

610-402-CARE LVHN.org

Lehigh Valley Health Network