Lehigh Valley Health Network
LVHN Scholarly Works

Department of Medicine

Role of 68Ga-DODATATE PET/CT in Staging and Management of Gastroenteropancreatic Neuroendocrine Tumor Management - A Case Series Report.

Abdul Aleem MBBS
Lehigh Valley Health Network, fnu_abdul.aleem@lvhn.org

Patrick Hickey DO
Lehigh Valley Health Network, Patrick.Hickey@lvhn.org

Shashin Shah MD
Lehigh Valley Health Network, Shashin.Shah@lvhn.org

Hiral N. Shah MD
Lehigh Valley Health Network, hiral_n.shah@lvhn.org

Follow this and additional works at: https://scholarlyworks.lvhn.org/medicine

Part of the Gastroenterology Commons, Internal Medicine Commons, and the Medical Sciences Commons

Published In/Presented At

Aleem, A. Hickey, P. Shah, S. Shah, H. (2017, October 17). *Role of 68Ga-DODATATE PET/CT in Staging and Management of Gastroenteropancreatic Neuroendocrine Tumor Management - A Case Series Report.* Poster Presented at: ACG World Conference, Orlando,FL.

This Poster is brought to you for free and open access by LVHN Scholarly Works. It has been accepted for inclusion in LVHN Scholarly Works by an authorized administrator. For more information, please contact LibraryServices@lvhn.org.

Role of ^{68}Ga-DODATATE PET/CT in Staging and Management of Gastroenteropancreatic Neuroendocrine Tumor Management - A Case Series Report

Abdul Aleem MD[1], Patrick Hickey DO[2], Shashin Shah MD2 and Hiral N.Shah MD[2]

[1]Department of Internal Medicine, [2]Department of Gastroenterology, Lehigh Valley Health Network, Allentown, Pennsylvania

BACKGROUND

- Gastroenteropancreatic (GEP) neuroendocrine tumors (NETs) are a group of neoplastic tumors arising from the diffuse neuroendocrine system of the gastrointestinal tract and pancreas.
- Although considered to be a rare entity, the incidence of GEP NETs has increased by 720% according to the US Surveillance Epidemiology and End Results (SEER) databases owing to increased awareness and improved diagnostic techniques.
- Assessment of the location of GEP NETs are crucial in the management of GEP NETs
- Various imaging modalities like Octreoscan®, 18F FDG PET/CT, CT, MRI and the recently approved 68Ga-DOTATATE PET/CT are currently used for diagnosis of GEP NETs.

CASE PRESENTATION

Case 01

- A 47-year-old female was admitted for evaluation of persistent abdominal cramping and bloating.
- CT Abdomen and Pelvis (Image 1a) showed 3.1 x 2.6 x 2.7 cm enhancing soft tissue mesenteric mass involving adjacent small bowel loops with features of small bowel obstruction.
- Surgical evaluation showed an infiltrative small bowel mass in the proximal ileum causing mechanical obstruction with proximal bowel dilation and adjacent lymphadenopathy.
- She underwent mesenteric mass, small bowel and lymph node resection with histopathology showing a low-grade neuroendocrine tumor.
- Further evaluation with ^{68}Ga-DOTATATE PET/CT (Image 2a and 2b) was suggestive of extensive hepatic metastases (confirmed by biopsy) which were not reported on the CT Abdomen (Image 1b).
- She is managed on chemotherapy as an outpatient.

Case 02

- A 72-year-old female was admitted for five months of persistent abdominal discomfort.
- CT Abdomen (Image 3) showed peripancreatic abnormality.
- Endoscopic Ultrasound with biopsy of the peripancreatic lymph node showed well differentiated neuroendocrine carcinoma.
- Octreoscan showed findings similar to the CT Abdomen.
- Further evaluation with 68Ga-DOTATATE PET/CT scan (Image 4a and 4b) showed hyperactive octreotide-avid peripancreatic and portocaval metastatic lymphadenopathy.
- Patient underwent Whipple's procedure and is currently being followed with serial 68Ga-DOTATATE PET/CT scans with no disease recurrence despite the primary still not being determined.

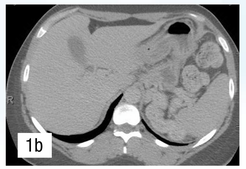

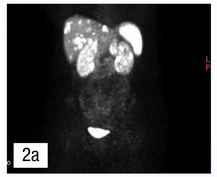

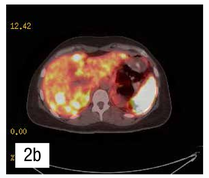

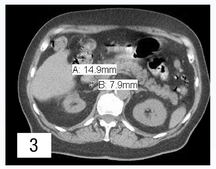

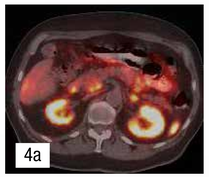

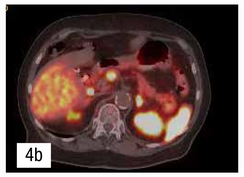

DISCUSSION

- ^{68}Ga-DOTATATE PET/CT provides enhanced diagnostic information compared to other approved imaging and it has been proven to have significant impact in management of patients with NETs.
- Haug et al showed 68Ga-DOTATATE PET/CT to be more sensitive, specific and accurate in cases of GEP NETs.
- Our case series illustrates the importance of further evaluating confirmed cases of GEP NETs with 68Ga-DOTATATE PET/CT scan, as this may change staging and ultimate treatment decisions.
- It also highlights the importance of keeping GEP NETs on the differential in evaluating patients with persistent abdominal pain despite extensive workup, as it was the presenting symptom in all of our cases.

References:

1. Alireza Mojtahedi, Sanjay Thamake, Izabela Tworowska, David Ranganathan, Ebrahim S Delpassand.The value of 68Ga-DOTATATE PET/CT in diagnosis and management of neuroendocrine tumors compared to current FDA approved imaging modalities: a review of literature. *Am J Nucl Med Mol Imaging* 2014;4(5):426-434.
2. Irvin M Modlin, Kjell Oberg, Daniel C Chung, Robert T Jensen, Wouter W de Herder, Rajesh V Thakker, Martyn Caplin, Gianfranco Delle Fave,Greg A Kaltsas, Eric P Krenning, Steven F Moss, Ola Nilsson, Guido Rindi, Ramon Salazar, Philippe Ruszniewski, Anders Sundin Gastroenteropancreatic neuroendocrine tumours. *Lancet Oncol* 2008; 9: 61–72.
3. Haug AR, Cindea-Drimus R, Auernhammer CJ, Reincke M, Beuschlein F, Wängler B, Uebleis C, Schmidt GP, Spitzweg C, Bartenstein P, Hacker M. Neuroendocrine tumor recurrence: diagno¬sis with 68Ga-DOTATATE PET/CT. *Radiology* 2014; 270: 517-25.

© 2017 Lehigh Valley Health Network

610-402-CARE LVHN.org

Lehigh Valley Health Network