

Mucosal advancement anoplasty.

Indru Khubchandani MD
Lehigh Valley Health Network, Indru.Khubchandani@lvhn.org

Follow this and additional works at: <https://scholarlyworks.lvhn.org/surgery>



Part of the [Medicine and Health Sciences Commons](#)

Published In/Presented At

Khubchandani I. T. (1985). Mucosal advancement anoplasty. *Diseases of the colon and rectum*, 28(3), 194–196. <https://doi.org/10.1007/BF02554245>

This Article is brought to you for free and open access by LVHN Scholarly Works. It has been accepted for inclusion in LVHN Scholarly Works by an authorized administrator. For more information, please contact LibraryServices@lvhn.org.

Technical Notes

JOHN A. COLLIER, M.D., *Editor*

Mucosal Advancement Anoplasty

INDRU T. KHUBCHANDANI, M.D.

Khubchandani IT. Mucosal advancement anoplasty. *Dis Colon Rectum* 1985;28:194-196.

[Key words: Anoplasty; Martin anoplasty; Anal Stenosis; Anal stricture; Anal rectal surgery]

ANAL STENOSIS is an abnormal narrowing of the anal canal due to contracture of the epithelial lining which, to a varying extent, has been supplanted by fibrous connective tissue. The resulting stricture scarcely permits the passage of formed stool. Patients frequently increase their consumption of laxatives to stimulate defecation. The inelastic scar may stretch and occasionally tear, exacerbating the stenosis as scar tissue reforms. Inflammation of the anus and lower rectum predisposes to stenosis, and breaches in the skin often produce concurrent infection. When the anal skin is excised extensively, as in radical hemorrhoidectomy, stenosis is not an uncommon sequela. In fact, iatrogenic anal stenosis is the most common indication for correction. Other, less frequent predisposing conditions include fistulectomy, pull-through procedures, obstetric or general trauma and rarely, involutonal senile stenosis. Specific infections associated with Crohn's disease, lymphogranuloma venereum, tuberculosis, and radiation also occasionally produce stenosis.

Diagnosis is made from the patient history and a physical examination. Inability to admit the examining finger or a standard dimension instrument is diagnostic, although the latter is not a definite indication for surgical correction. The bowel may be inspected proximally with a narrower stricturoscope. Melanosis coli resulting from laxative abuse often is evident. The site of the scar should be recorded, as should areas of mucosal prolapse, if any.

Several plastic procedures have been described which require extensive dissection. S-plasty¹ and Y-V-plasty² procedures advance external skin into the scarred anal canal. Stretching of the anus (divulsion of the sphincter)

From the Division of Colon and Rectal Surgery, Allentown Affiliated Hospitals, Allentown, Pennsylvania

risks tearing this tissue with resultant intrasphincteric ecchymosis and exacerbation of contracture. Lasting repair should correct the stenosis and prevent its recurrence.

Mucosal Advancement Anoplasty is a simple corrective option for surgical repair of symptomatic anal stenosis. It has produced salutary outcomes in the majority of patients reported here. This technique is a modification of the Martin anoplasty³ for anal stenosis performed with local anesthesia. Excision of scar tissue is followed by either unilateral or bilateral internal sphincterotomy. The mucosa is advanced over the internal sphincter, thereby preventing recurrence of contracture by scarring.

Martin's procedure uses a posterior midline incision and advancement of mucosal flap following excision of the scar tissue and sphincterotomy. The internal sphincterotomy corrects stenosis and, by covering the distal portion with mucosa, prevents scar formation. However, posterior midline incisions pose an unnecessary risk of key-hole deformities. We have modified this procedure to capitalize on the superiority of lateral anal sphincterotomy. The modified procedure is outlined as follows:

- 1) Stenosis is corrected by excision of scar tissue and internal sphincterotomy (unilateral or bilateral). Judicious sphincterotomy minimizes risk of subsequent incontinence.
- 2) Mucosal advancement prevents recurrence.
- 3) Mucosal ectropion is minimized by advancing the mucosa to, but not beyond, the anal verge.

Technique

Phosphosoda enemas are administered preoperatively. No antibiotics are used. Patients are usually awake but sedated during the procedure.

The patient is placed in the jack-knife position and infiltration of local anesthesia is performed as we have previously reported for hemorrhoidectomy.⁴ Whenever possible, a small Hill-Ferguson retractor is inserted. Unlike Martin's procedure, the incision is made laterally

Supported in part by a grant from the Dorothy Rider Pool Health Caré Trust.

Read at the meeting of the American Society of Colon and Rectal Surgeons, Boston, Massachusetts, June 5 to 9, 1983.

Address reprint requests to Dr. Khubchandani: Division of Colon and Rectal Surgery, Lehigh Valley Hospital Center, 1200 South Cedar Crest Boulevard, Allentown, Pennsylvania 18015.

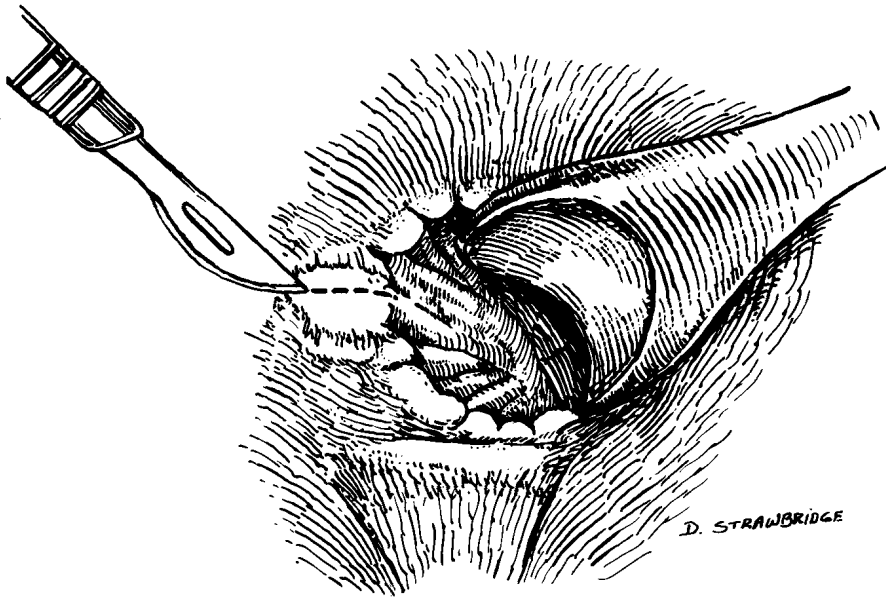


FIG. 1. Incision from dentate line to external verge.

at a perpendicular to the dentate line and is extended to the anal verge (Fig. 1). Excision of underlying scar tissue and internal sphincterotomy permit admission of a medium Hill-Ferguson retractor. The mucosa is undermined at the dentate line for a length varying from 2 to 5 cm (Fig. 2). A transverse wound results from gaping of the tissues. The fringe of the scar tissue at the margin of the mucous membrane is excised. The mucosa is sutured to the subcutaneous tissue at the anal verge with several interrupted sutures of 5-0 Dexon (Fig. 3). The external part of the wound is left open. The contralateral side is treated similarly to permit easy entry of a large Hill-Ferguson retractor (Fig. 4). Packing and postoperative anti-

biotics are eschewed. Postoperative management is the same as for hemorrhoidectomy. Early bowel movement is encouraged by administration of bulk supplements. Patients usually are discharged on the day following surgery.

Results

Since 1968, we have performed 53 procedures (16 males and 37 females). The median age of the patients was 59 years. Their presenting complaints were the following: tightness (21), pain (20), bleeding (18), blockage (12), burning (9), and splitting (8). All patients had undergone previous anorectal surgery, including one patient who

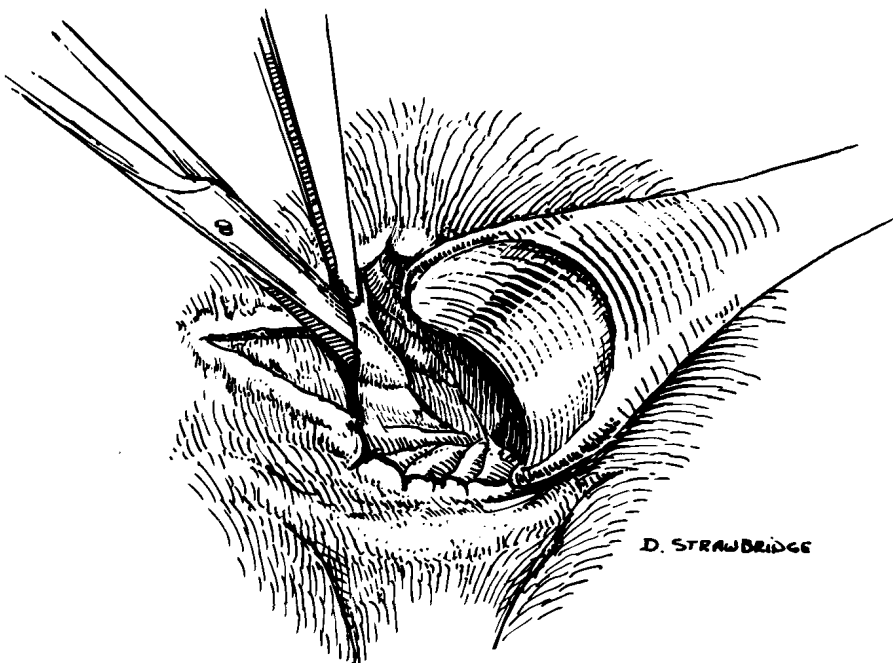


FIG. 2. Mucosa is undermined for 2 to 5 cm.

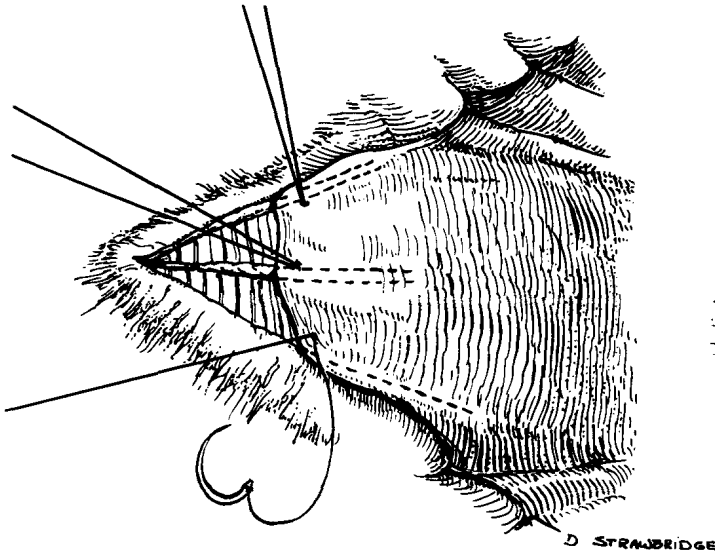


FIG. 3. Advanced mucosa is anchored to distal border of internal sphincter with interrupted 5-0 Dexon.




FIG. 4. Result of a bilateral mucosal advancement anoplasty.

suffered stenosis following the Bacon pull-through procedure. Forty-four patients required bilateral repair and nine unilateral. The average healing time was 16 days. Two patients were lost to follow-up, leaving 51 patients available for long-term follow-up.

If the anal canal admitted a standard 19 mm sigmoidoscope and symptoms were markedly relieved, the outcomes were classified as good. Symptom relief in patients who experienced mild discomfort during insertion of the sigmoidoscope was designated as fair. Persistent symptoms and stenosis, incontinence, or ectropion marked patients with poor outcome. Good outcomes were ob-

tained for 42 patients (82.3 percent), satisfactory for six (11.8 percent), and poor outcomes for three (5.9 percent).

References

1. Ferguson JA. Repair of "Whitehead deformity" of the anus. *Surg Gynecol Obstet* 1959;108:115-6.
2. Oh C, Zinberg J. Anoplasty for anal stricture. *Dis Colon Rectum* 1982;25:809-10.
3. Martin EG. The plastic use of skin in simple anal stricture, reconstruction of anal lining, pilonidal disease. *Tr Am Proct Soc* 1944;44:195-200.
4. Khubchandani IT, Trimpi HD, Sheets JA. Closed hemorrhoidectomy with local anesthesia. *Surg Gynecol Obstet* 1972;135:955-7.